

Propranolol Treatment in the Management of Infantile Hemangioma in Erbil, Iraq

Wesam Amjad Boya Kaka*, Siamand Yahya Salim, Jalal Hamasalih Fattah

College of Medicine, Hawler Medical University, Erbil, Kurdistan Region-Iraq

ABSTRACT

Background: Infantile hemangioma is a common benign vascular tumor that affects up to 10% of infants. Propranolol, a beta-blocker, has been used as a promising treatment for infantile hemangioma, but its effectiveness remains controversial. Therefore, the aim of the current study was to investigate the effect of propranolol in the treatment of infantile hemangioma in Erbil, Iraq.

Methods: This prospective interventional study was conducted between May 2021 and December 2022 at Rapareen Teaching Hospital in Erbil, Iraq. A total of 42 children entered the study, considering the inclusion criteria. Propranolol was given at a dose of 1 mg/kg/day and increased to 2-3 mg/kg/day within a few days if tolerated. Infants were treated and followed up for 3 to 6 months. During this follow-up, the infants were checked for cardiac, respiratory, and hypoglycemic symptoms. The obtained data were analyzed using paired, independent, and chi-square tests.

Results: The mean age of the infants was 11.48 ± 5.251 months. Regarding the gender distribution of the participants, 14 (33.3%) of the infants were males and 28 (66.7%) were females. Hemangiomas were observed in different body regions, including 6 (14.3%) cases in the limbs, 28 (66.7%) in the head and neck, and 8 (19%) in the trunk. Regarding the response to treatment, the results revealed that 27 (64.3%) infants responded well to the treatment. There was a moderate response in 9 (21.4%) infants and a mild response in 6 (14.3%) infants.

Conclusion: Based on the findings of this study, propranolol can be used as an effective and safe drug for hemangioma treatment.

Keywords: B-blockers, Infantile hemangiomas, Infants, Propranolol, Treatment, Therapeutic use

Introduction

Infantile hemangiomas (IHs) are the most common vascular tumors of infancy, affecting up to 5-10% of infants (1). The tumor typically appears during the first few weeks of life and grows rapidly during the first year, with most lesions reaching their maximum size by 6-9 months (2). Several factors have been associated with an increased risk of IH development, including prematurity, female gender, white ethnicity, a positive family history of vascular anomaly, low birth weight, multiple gestations, or advanced maternal age (3, 4).

Although most IHs resolve spontaneously, in

some cases, IHs can cause functional impairment, disfigurement, or life-threatening complications, such as airway obstruction, hemorrhage, or heart failure. Therefore, IH management depends on various factors, such as location, size, growth pattern, and potential complications (5, 6).

Historically, the treatment of IHs relied on surgical excision, intralesional corticosteroid injection, or laser therapy, marked by variable success rates and potential side effects (4). However, the discovery of the therapeutic effect of propranolol on IHs in 2008 by Léauté-Labrèze et al. has revolutionized IHs management (7). Propranolol, a

* Corresponding author: Wesam Amjad Boya Kaka, College of Medicine, Hawler Medical University, Erbil, Kurdistan Region, Iraq. Email: wesam.kaka@hmu.edu.krd

Please cite this paper as:

Amjad Boya Kaka W, Yahya Salim S, Hamasalih Fattah J. Propranolol Treatment in the Management of Infantile Hemangioma in Erbil, Iraq. Iranian Journal of Neonatology. 2024 Jan; 15(1). DOI: [10.22038/IJN.2023.74336.2439](https://doi.org/10.22038/IJN.2023.74336.2439)



beta-blocker, induces vasoconstriction, reduces angiogenesis, and promotes the involution of the lesion by targeting the beta-adrenergic receptors on the endothelial cells of the blood vessels (8). Nowadays, propranolol is accepted as the first-line treatment for IHs. Therefore, The recommended oral dosage of propranolol starts at 1 mg/kg/day and increases to 2-3 mg/kg/day for at least 6 to 12 months. For further investigation, the ideal dosage is thought to be between 1.5 and 2.0 mg/kg per day (9).

The results of a study by Léaute-Labrèze et al. (2016) showed that oral propranolol could be well tolerated, and serious side effects were minimized during treatment when proper evaluations were performed before and during treatment (10). Turhan et al. (2016) found that propranolol was a tolerable, effective, and safe drug for IH treatment and could be started and administered in an outpatient setting (11). Treatment with propranolol is useful, but it can also cause side effects considering factors, such as ethnicity. Considering factors such as ethnicity, which can affect infant hemangiomas, and the limited studies conducted in Iraq, there is a need to conduct this study with the aim of investigating the effect of propranolol on the treatment of neonatal hemangioma in Erbil, Iraq.

Methods

This prospective interventional study was conducted between May 2021 and December 2022 at Rapareen Teaching Hospital in Erbil, Iraq. Data collection involved recording the age, gender and weights of children who were taking propranolol. Given the study's nature as a census, where all available infants were included, specific details regarding the sampling method and sample size were not provided. Monthly dosing adjustments were made based on the child's weight, and were recorded by the researchers.

Inclusion criteria included infants aged two years or younger, confirmed diagnosis of infantile hemangioma by clinical examination or imaging studies, informed parental consent, and no contraindications to propranolol.

Infants who were unwilling to cooperate, patients with contraindications to propranolol, such as asthma or heart failure, patients who did not complete the follow-up period, and those with incomplete or insufficient information were excluded from the study.

A total of 42 infants were included in the study. These infants were then followed up at an outpatient clinic in Rapareen Teaching Hospital,

Erbil, Iraq, pecifically designed for children and the private clinic of the investigators. After the prescription of propranolol, these infants were tracked over a mean follow-up period ranging from 3 to 6 months.

Water was used to dilute the propranolol pill (10 mg) for administration. Newborns received an initial oral dosage of 1 mg/kg/day. In case no significant side effects were observed during inpatient monitoring, the dosage was raised to 2-3 mg/kg/day within a few days. Infants were planned to be treated and followed up for 3 to 6 months. During the first days, the medicine was prescribed in the hospital under supervision and the infants were surveyed for side effects. Subsequently, parents received the necessary training about the side effects of the medicine. In the first two or three days of therapy, hypoglycemia, cardiologic, and respiratory monitoring were conducted one to three times daily. Further monitoring was carried out once a week for the first month, followed by monthly check-ups until the completion of the treatment.

The efficacy of treatment was evaluated based on the classification system introduced by Achauer et al. incorporating parent feedback (12). This classification system categorizes outcomes into four groups, namely poor (reduction of 25%-26% of tumor volume), moderate (reduction of 50%-51% of tumor volume), good (reduction of 75%-76% of tumor volume), and excellent (reduction of 100%-100% of tumor volume). Adverse effects of treatment were also recorded.

Upon data collection, statistical analysis was performed using SPSS version 26 (IBM SPSS Statistics for Windows, Version 26.0. Armonk, NY: IBM Corp). P value less than 0.05 was considered statistically significant. The qualitative variables were expressed as frequency (percentage), and quantitative variables were presented as mean \pm SD. Logistic regression was used to check the factors influencing the treatment.

Informed consent was obtained from all participants' parents before participating in the study. In this study, the Declaration of Helsinki was followed in order to comply with ethical principles.

Ethical approval

An informed consent was obtained from all participants parents before participating in the study. In this study, the Declaration of Helsinki was followed in order to comply with ethical principles. This research study has approved by ethical committee of Hawler Medical

University(7/10-2/5/2023).

Results

The mean age of the infants was $11.48 \pm (5.251)$ months. Among the infants, 14 (33.3%) of the infants were male. Further analysis of the infants' age revealed that 16 (38.1%) of them were under 10 months old, and 26 (61.9%) were 10 months and older. The mean age of the mothers in this study was $27.41 \pm (3.84)$ years. Additionally, the mean weight of the infants was $7.11 \pm (2.5)$ kg. Of the infants, 22 (52.38%) were first-born infants, 15 (35.7%) were second-born infants, and 5 (11.92%) were third-born infants. Moreover, 39 (92.8%) infants had no family history of the disease (Table 1). It was also found that 6 (14.3%) cases had hemangioma in the limbs, 28 (66.7%) in the head and neck, and 8 (19%) people had hemangioma in the trunk (Figure 1).

The mean tumor size in infants was $27.41 \pm (3.84)$ cm. The results of the treatment period variable in infants showed that 1 (2.4%) case had a 2-month treatment period, and a 3-month

treatment period was observed in 23 (59.5%) cases. Treatment periods of 4-5 months were recorded in 4 (9.5%) cases, and 8 (19%) cases had a treatment period of 6 months (Table 2).

In the study, 8 (19%) infants had side effects caused by the use of medicine. The results of examining the recurrence rate variable in infants showed that 5 (11.9%) infants had disease recurrence (Figure 2).

Table 1. The basal characteristics of the patients

Variable	Characteristic	Frequency (%)
Sex	Male	14 (33.3%)
	Female	28 (66.7%)
Age group	< 10	16 (38.1%)
	≥ 10	26 (61.9%)
Age infants (month)		$11.48 \pm (5.251)$
Mother's age (years)		$27.41 \pm (3.84)$
Weight infants (kg)		$7.11 \pm (2.5)$
Child order	First	22 (52.38%)
	Second	15 (35.7%)
	Third	5 (11.92%)
Family history	No	39 (92.8%)
	Yes	3 (7.2%)

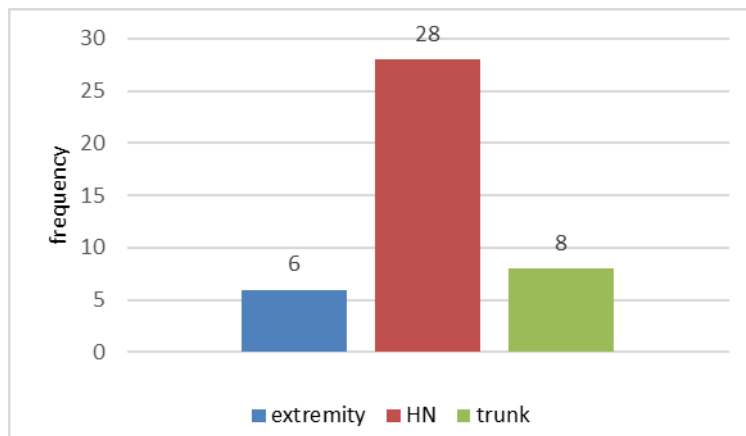


Figure 1. site of Hemangioma in the patient

Table 2. The clinical characteristics of the patients

Characteristic	Frequency (%)	
Mean tumor area (cm)	9.5 ± 8.4	
Duration of treatment in months	2	1 (2.4%)
	3	23 (59.5%)
	4	4 (9.5%)
	5	4 (9.5%)
	6	8 (19%)
Side effect	Yes	8 (19%)
	No	34 (81%)
Recurrence	Yes	5 (11.9%)
	No	37 (88.1%)
Response	Good	27 (64.3%)
	Moderate	9 (21.4%)
	Mild	6 (14.3%)

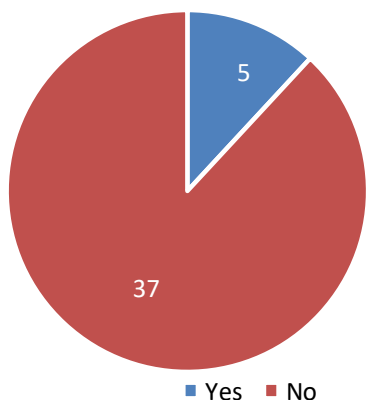


Figure 2. Recurrence Hemangioma in the patient

The rate of response to treatment in the examined infants revealed that in 27 (64.3%) infants, the treatment had a good response and was successful. In 9 (21.4%) infants, the treatment had a moderate response, and in 6 (14.3%) infants, the treatment had a mild response (Figure 3).

The effect of treatment on the size and location of the tumor in the infants showed (Table 3) that the tumor size before treatment was 8.4 ± 9.5 cm

and after treatment was 3.6 ± 2.2 cm, indicating a significant decrease in tumor size ($P \leq 0.002$). Regarding the location of the tumor after the intervention, 1 tumor was in the extremity area, 4 tumors were in the HN area, and 1 tumor was in the trunk area. This demonstrated a significant difference in the intervention ($P \leq 0.001$).

The logistic regression analysis revealed several influential factors affecting the success of treatment in newborns. Age, weight of the baby, the size of the tumor, and the duration of the treatment could affect the success of the treatment. For every one-month increase in age, the success rate of treatment increased by 1% (OR = 1.01, $P = 0.02$, CI: 95% 1.002-1.024). Similarly, with an increase of one kilogram of the baby's weight, the treatment success rate increased by 20% (OR = 1.20, $P = 0.001$, CI: 95% 1.15-1.45). The size of the tumor was an essential factor in the success of the treatment, so with each centimeter increase in the size of the tumor, the success of the treatment increased by 9% (OR = 1.09, $P = 0.01$, CI: 95% 1.003-1.020). Moreover, an increasing in the treatment period by one month enhances the treatment success rate by 10% (OR = 1.10, $P = 0.02$, CI: 95% 1.004-1.28; Table 4)

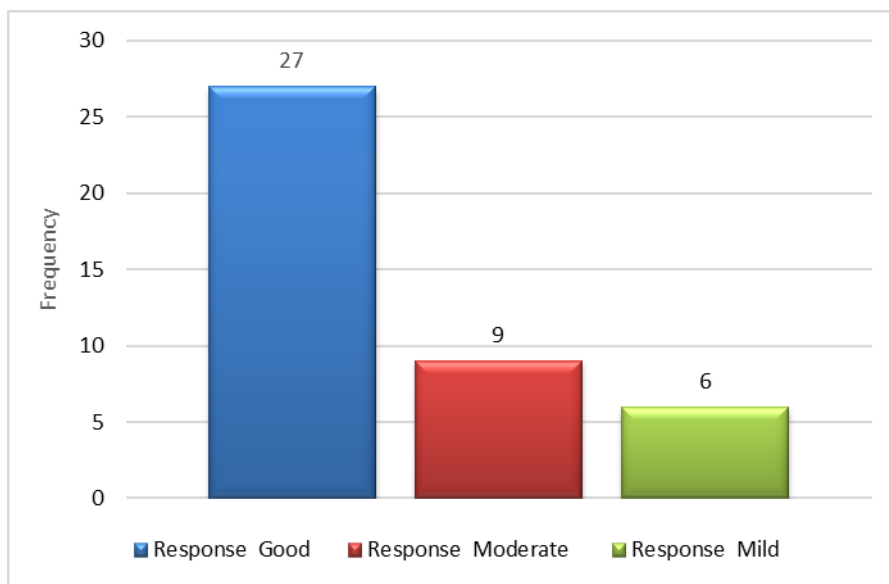


Figure 3. Response to treatment in the patient

Table 3. The effect of treatment on the size and location of the tumor in the examined infants

Parameter		Before intervention	After intervention	P-value
Mean tumor area		9.5 ± 8.4	2.2 ± 3.6	0.002
Site of hemangioma	Extremity	6	1	0.001
	HN	28	4	
	Trunk	8	1	

Table 4. Factors influencing the treatment

Factor	OR	P- Value	CI:95%
Age	1.01	0.02	1.002 - 1.024
Weight infants	1.20	0.001	1.15 - 1.45
Mean tumor area	1.09	0.03	1.003 -1.020
Duration of treatment in months	1.10	0.02	1.04 - 1.28

Discussion

The study explored the effectiveness of propranolol in treating infantile hemangioma, considering the limitations of alternative treatments like corticosteroids and vincristine which often lead to adverse side effects, such as growth retardation, hypercortisolism, eye complications, and stomach discomfort (13, 14). Propranolol emerged as a viable alternative, showing promising results in this study. It was found that 86% of infants treated with propranolol had successful treatment. The results showed a significant effect of propranolol on tumor size and tumor location so that it was associated with both the reduction of tumor size and the number of tumors.

A study conducted by Livani et al. (2016) in Iran, involving 30 infants with hemangioma, aligned with the current results. In their study, propranolol was administered orally, starting at 1 mg/kg/day and gradually increased to 2-3 mg/kg/day. Consistent with the results of the current study, their research emphasized that propranolol could be considered an effective and safe alternative to other drugs and could reduce the surgical interventions caused by hemangioma (15).

Giese et al. (2021) conducted a study in Canada to examine the effect of propranolol on the treatment of hemangioma and the effect of the drug on the normal growth process of infants. In this study, 185 children were treated with propranolol between 2008 and 2013. Data were collected prospectively. Their findings aligned with the results of the present study, demonstrating that propranolol, while effective in treating the disease, does not hinder the growth process of the child and could be used as a safe drug in treating the disease (16). In the studies conducted in China (17), Italy (18), and America (19), the efficacy and effectiveness of the drug in treating the disease has been confirmed.

Very rare complications, including extensive hypoglycemic coma (20) and cases of death (21), have been reported during the use of propranolol in the treatment of hemangioma. It should be noted that the early identification of these side

effects can be very important for the management and prognosis of the patient. This awareness is not only crucial for healthcare professionals but also holds significant importance in educating parents about potential complications. The results of the side effects analysis in this study indicated a lower incidence, compared to the results of other studies (22, 23).

The obtained results indicated the effectiveness of propranolol in reducing the size and number of tumors, which was supported by previous studies indicating that the administration of propranolol caused a decrease in the size and number of tumors (24) and (25).

Due to the fact that propranolol is considered a beta blocker at the forefront of hemangioma treatment, it is necessary to pay attention to the administration methods and pharmaceutical formulations. It is also important to explore new pharmaceutical forms to optimize its effectiveness while minimizing potential side effects (9).

Limitation

Study limitations include a small sample size, selection bias, and short follow-up periods. Addressing these limitations through careful study design, monitoring, and reporting is crucial to ensure the validity and applicability of the results. Further research is needed to overcome these limitations and provide a comprehensive understanding of the effectiveness and safety of propranolol use in the management of infantile hemangioma.

Conclusion

Based on the findings of this study, propranolol can be used as an effective, safe and drug for the treatment of infantile hemangioma. This medicine can be considered as a tolerable medicine with few side effects for infants in the treatment of the disease.

Acknowledgments

The authors would like to offer their heartfelt gratitude to everyone who assisted in the accomplishment of this research study. Children, parents, medical professionals, coworkers,

academic institutions, and other stakeholders contributed to the study's success.

Conflicts of interest

The authors declare that they have no conflicts of interest.

References

- Jung H. Update on infantile hemangioma. *Clin Exp Pediatr*. 2021;64(11):559-72.
- Leung A, Lam J, Leong K, Hon K. Infantile Hemangioma: An Updated Review. *Curr Pediatr Rev*. 2021;17(1):55-69.
- Castrén E, Salminen P, Gissler M, Stefanovic V, Pitkäranta A, Klockars T. Risk factors and morbidity of infantile haemangioma: preterm birth promotes ulceration. *Acta Paediatr*. 2016;105(8):940-5.
- Satterfield K, Chambers C. Current treatment and management of infantile hemangiomas. *Surv Ophthalmol*. 2019;64(5):608-18.
- Léauté-Labrèze C, Harper JI, Hoeger PH. Infantile haemangioma. *The Lancet*. 2017;390(10089):85-94.
- Joseph J, Wain T. Infantile haemangiomas: Identifying high-risk lesions in primary care. *Aust J Gen Pract*. 2021;50(12):887-92.
- Sebaratnam D, Rodríguez Bandera A, Wong L, Wargon O. Infantile hemangioma. Part 2: Management. *J Am Acad Dermatol*. 2021;85(6):1395-404.
- Ali A, Herndon DN, Mamachen A, Hasan S, Andersen CR, Grogans RJ, et al. Propranolol attenuates hemorrhage and accelerates wound healing in severely burned adults. *Crit Care*. 2015;19(1):217.
- Tan X, Guo S, Wang C. Propranolol in the Treatment of Infantile Hemangiomas. *Clin Cosmet Investig Dermatol*. 2021;14:1155-63.
- Léaute-Labrèze C, Boccara O, Degrugillier-Chopin C, Mazereeuw-Hautier J, Prey S, Lebbé G, et al. Safety of Oral Propranolol for the Treatment of Infantile Hemangioma: A Systematic Review. *Pediatrics*. 2016;138(4):e20160353.
- Turhan AB, Bör Ö, Özdemir ZC. Treatment with propranolol for infantile hemangiomas: single-center experience. *J Cosmet Dermatol*. 2016; 15(3):296-302.
- Achauer BM, Chang CJ, Vander Kam VM. Management of hemangioma of infancy: review of 245 patients. *Plast Reconstr Surg*. 1997;99(5):1301-8.
- Liu Q, Xiong N, Gong X, Tong H, Tan X, Guo X. Cocktail therapy with prednisolone, vincristine and sirolimus for Kasabach-Merritt phenomenon in 10 infants. *Exp Ther Med*. 2022 Aug 9;24(4):621.
- Cohen-Cutler S, Detterich JA, Miller JM, Anselmo DM, Luu M, Mascarenhas L. Mediastinal infantile hemangioma with spinal canal extension and extensive gastrointestinal involvement complicated by respiratory failure. *Pediatr Blood Cancer*. 2022;69(11):e29934.
- Livani F, Layegh P, Alizadeh B, Tashnizi MA, Amin Moghaddam M, Taherian A. Propranolol for infantile hemangioma: An evaluation of its efficacy and safety in Iranian infants. *Iran J Neonatol*. 2016;7(3):17-20.
- Giese RA, Turner M, Cleves M, Gardner JR, Richter GT. Propranolol for Treatment of Infantile Hemangioma: Efficacy and Effect on Pediatric Growth and Development. *Int J Pediatr*. 2021;2021:6669383.
- Yuan W, Wang X. Propranolol Participates in the Treatment of Infantile Hemangioma by Inhibiting HUVECs Proliferation, Migration, Invasion, and Tube Formation. *Biomed Res Int*. 2021;2021:6636891.
- Pensabene M, Di Pace MR, Baldanza F, Grasso F, Patti M, Sergio M, et al. Quality of life improving after propranolol treatment in patients with Infantile Hemangiomas. *Ital J Pediatr*. 2022;48(1):140.
- Seebauer CT, Graus MS, Huang L, McCann A, Wylie-Sears J, Fontaine F, et al. Non-beta blocker enantiomers of propranolol and atenolol inhibit vasculogenesis in infantile hemangioma. *J Clin Invest*. 2022;132(3):e151109.
- Bakalli I, Kola E, Lluca R, Celaj E, Sala D, Gjeta I, Sallabanda S, Klironomi D. Deep coma in a child treated with propranolol for infantile hemangioma. *BMC Pediatr*. 2019;19(1):1-3.
- Pathman L, Domp Martin A, Coquerel A, Robertson S, Phillips R. Unexplained Infant Deaths While on Propranolol for Treatment of Infantile Hemangiomas. *Journal of Vascular Anomalies*. 2022;3(1):e033.
- Sasaki M, North P, Elsej J, Bublej J, Rao S, Jung Y, et al. Propranolol exhibits activity against hemangiomas independent of beta blockade. *NPJ Precis Oncol*. 2019;3:27.
- Kaushik S, Kataria P, Joshi G, Singh R, Handa S, Pandav S, et al. Perioperative Propranolol: A Useful Adjunct for Glaucoma Surgery in Sturge-Weber Syndrome. *Ophthalmol Glaucoma*. 2019;2(4):267-74.
- Koh M, Takahashi T, Kurokawa Y, Kobayashi T, Saito T, Ishida T, et al. Propranolol suppresses gastric cancer cell growth by regulating proliferation and apoptosis. *Gastric Cancer*. 2021;24(5):1037-49.
- Albiñana V, Gallardo-Vara E, Casado-Vela J, Recio-Poveda L, Botella LM, Cuesta AM. Propranolol: A "Pick and Roll" Team Player in Benign Tumors and Cancer Therapies. *J Clin Med*. 2022;11(15):4539.