

A Narrative Review of Ultrasonographic Features of Umbilical Lesions in Children and Our Experience

Seyed Ali Alamdaran¹, Alireza Ataei Nakhaei¹, Ehsan Hassan Nejad², Amir Behforouz^{3*}

1. Dr. Sheikh Children Hospital, Mashhad University of Medical Sciences, Mashhad, Iran

2. Department of Radiology, School of Medicine, Birjand University of Medical Sciences, Birjand, Iran

3. Department of Radiology, School of Medicine, Mashhad University of Medical Sciences, Mashhad, Iran

ABSTRACT

Background: The umbilicus is the fibrous remnant of the fetal attachment of the umbilical cord. Ultrasonography is the preferred imaging modality for the evaluation of umbilical lesions. We present our experience and a review of ultrasound findings of umbilical lesions in children that may differentiate these lesions.

Methods: A query was conducted on online databases to identify and review articles in English studying umbilical lesions and their ultrasound features in children until September 2022. In some cases, the authors' unpublished experiences were also used due to insufficient ultrasound information in the literature.

Results: The thickness of the normal urachus is 2.5- 4 mm in newborns, and after the infancy period, it reduces to less than 2 mm. An increase in its thickness, generally or focally, indicates a patent urachus or urachal sinus. The normal cord or its remnant is observed as a hypoechoic mass surrounded by an elevated skin ring during infancy. The abdominal extension of the cord remnant suggests a patent urachal or omphalomesenteric remnant. On ultrasound, umbilical polyps are deep-seated lesions with mixed or hyper-echoic echo texture that can help differentiate them from umbilical cord remnants or umbilical granulomas. Ultrasonographic findings of omphalitis or the infected cord remnant are enlarged umbilicus as a large mass-like lesion associated with edema of peri-umbilical skin and subcutaneous tissues.

Conclusion: As evidenced by the results of this study, ultrasound can be used as a valuable complementary assessment tool for clinicians, allowing for assessing umbilical lesions and choosing the correct approach to treating these lesions.

Keywords: Omphalomesenteric duct, Ultrasound, Umbilical lesion, Umbilicus, Urachus

Introduction

In the fetal period, the umbilical veins, arteries, and urachus pass through the umbilicus. After the umbilical cord stump falls off, all layers of the anterior abdominal wall fuse at the umbilical ring as a small round defect in the linea alba called umbilical scar (cicatrix). The umbilicus is the fibrous remnant of the fetal attachment of the umbilical cord (1). Defects in the expected closure of cord tissues after birth lead to umbilical hernia, urachus lesions, or omphalomesenteric duct disorders in infancy. Umbilical masses, such as umbilical cord remnant, umbilical granuloma, and polyps, are other umbilical lesions (2). Vascular, infectious, or inflammatory lesions are another

part of navel diseases. The clinical manifestations of these lesions are usually nonspecific (3), and umbilical swelling and discharge are chief patient complaints (4). Peri-umbilical discharge occurs in patent urachus, patent omphalomesenteric duct, umbilical granuloma, and dermatitis (5).

Most umbilical diseases are treated with medical and conservative treatment, and surgery is required in a few cases. Understanding the abnormalities of the umbilicus is crucial for arriving at the correct diagnosis, the differentiation of which is essential for adopting an appropriate therapeutic approach until surgical treatment, offering proper patient treatment, planning surgery, timely initiation of the

* Corresponding author: Amir Behforouz, Department of Radiology, School of Medicine, Mashhad University of Medical Sciences, Mashhad, Iran, Tel: +989155796318; Email: Behforouza981@mums.ac.ir

Please cite this paper as:

Alamdaran A, Ataei Nakhaei A, Hassan Nejad E, Behforouz A. A Narrative Review of Ultrasonographic Features of Umbilical Lesions in Children and Our Experience. Iranian Journal of Neonatology. 2023 April; 14(2). DOI: 10.22038/ijn.2023.69244.2341

correct treatment, minimizing diagnostic errors, and decreasing the risk of associated complications (4, 6). Occasionally, corrective surgical interventions may be urgently required (7), such as in the case of an unrecognized band resulting in bowel volvulus. In addition, the concomitance of two umbilical lesions is common (8).

Imaging modalities can help establish the diagnosis of umbilical disorders. In the past, in patients with peri-umbilical discharge, fistulography with the injection of radio-contrast material into the umbilical opening was the study of choice since it allowed the diagnosis of a patent urachus or patent omphalomesenteric duct (8). High-resolution ultrasonography is the preferred imaging modality for evaluating umbilical lesions. It can yield information on the anatomical and structural properties of umbilical lesions and help determine the appropriate treatment.

The advantages of ultrasound are the possibility of doing it in outpatient clinics and no exposure to radiation(9). Magnetic resonance imaging (MRI) or computed tomography (CT) scan may be considered when ultrasonography is non-diagnostic (8). In this paper, we report an in-depth review and our experience of sonographic features of umbilical lesions that are helpful in the differential diagnosis of umbilical pathologies in children.

Methods

An online literature search in online databases, including Web of Science, Medline, Scopus, EMBASE, and Google Scholar, was used to identify English articles on umbilical lesions and their ultrasound features in children until September 2022. Keywords queried included various arrangements of the following terms: "Ultrasound," "US," "Umbilicus," "Urachus," "omphalomesenteric duct," and "Umbilical lesion." The articles that reported Umbilical lesions, Ultrasound findings and were not written in English were excluded. Additional queries were performed based on the relevant references of the searched articles as well. In some cases, the authors' unpublished experiences were also used due to insufficient ultrasound information in the literature.

Results

Finally, 34 studies on sonography in Umbilical lesions were included in our review. The summarized findings of these studies are categorized concerning the pathophysiology in the following paragraphs. Table 1 summarizes the ultrasonographic findings of umbilical lesions in children.

Table 1. Ultrasonographic findings of Umbilical Lesions in children

Umbilical lesions	Pathology	Sonographic features
Hernia	Umbilical or Para-Umbilical	Abdominal wall defect and protrusion of a bowel loop into the umbilicus or adjacent linea alba(11)
	Cord remnant	Deep-seated severe hypoechoic nodule
Masses	Granuloma	Hypoechoic nodule inside the umbilicus without any extension through the peritoneum or sinus track(6) / hypervascular superficial solid nodules(14) / hypervascularity can be suggestive of acute infection(11)
	Polyps	Deep-seated hyperechoic mass with hypo-vascularity. Originated from enteric or urachal remnant(14)
	Others	Skin tag, Lipoma, ...
	Urachal Sinus	Focal thickened tubular structure adjacent to the umbilicus without any communication to the urinary bladder (3, 17-20)
Urachal	Patent Urachus	Hypoechoic tubular structure, which communicates the bladder and umbilicus(18-20) / change of size of tubule during micturition(20)
	Urachal cyst	Extra-peritoneal thin-walled, midline cystic structure along the course of the urachus(3, 18-20)
	Urachal diverticulum	Super-infection: thick wall collection with peripheral hyper-vascularity(11, 17) Extra-luminally protruding diverticulum arising from bladder dome(3, 17-20)/ change of size of tubule with bladder filling(20) Super-infection: focal thick wall diverticulum
Omphalomesenteric(vitelline) duct	Vitelline fistula	Communication of the herniated bowel with the base of a protruding umbilical mass(25) / a cystic lesion in the anterior abdominal wall at the level of the umbilicus(23)
	Vitelline band	Hyperechoic striated band extending to the umbilicus(26)
	Vitelline sinus	A multi-layered structure attached to the umbilicus
	Vitelline cyst	A multi-layered wall cyst attached to the abdominal wall at the midline(24)
	Meckel's diverticulum	Tubular blind-ending structure in the right lower quadrant with gut signature sign(28, 29) / blind-ended cystic mass with a thick echogenic wall and clear or turbid content(pseudogestational sac sign)(32)
Inflammation	Dermatitis	Hypoechoic thickening of the umbilical derma with clinical symptom
	Omphalitis	Enlarged umbilicus with the hyper-vascular peri-umbilical edema(37)
	Omphalophelebitis	Focal or disseminated increase in size and thickness of the vein with intra-luminal clots

Normal Umbilicus and Related Tissues

In children and adults, the umbilicus comprises a central scar in the linea alba (cicatrix) surrounded by an elevated high margin of smooth or wrinkled skin. The urachal remnant is more visible below the umbilicus and at the anterosuperior surface of the urinary bladder (dome of the bladder). It is observed as a rat-tail hypoechoic band in the sagittal view. In the transverse view, this hypoechoic band is seen as an elliptical hypoechoic structure that can be traced to the bladder dome. Normal urachal remnant is detected in 62% of all bladder sonograms (6). The thickness of the normal urachus is 2.5- 4 mm in newborns, and after the infancy period, it reduces to less than 2 mm. An increase in its thickness, generally or focally, indicates a patent urachus or urachal sinus.

The umbilical vein is often observed above the umbilicus as a collapsed ovoid structure in the depth of the abdominal wall. The umbilical vein remnant forms the ligamentum teres (round ligament). It may be abnormally reopened, especially in portal hypertension. The rest of the umbilical arteries include medial umbilical ligaments. They may be abnormally patent and cause bleeding at the umbilicus. Gradually, they become echogenic and calcified, visible in the umbilicus and the para-median plane (Figure 1). The vitelline duct remnant is not visible except in pathologic states.

Umbilical Pathologies

Umbilical Hernia

An umbilical hernia is the most common umbilical problem in children. It is a protrusion of a bowel loop or omentum from the abdominal wall through the umbilicus (umbilical) or the peri-umbilical area (para-umbilical hernia). This condition is caused by a failure in the expected closure of the fetal umbilical ring due to the physiologic herniation of the bowel (4). The vast majority of such cases are spontaneously resolved during the first three years of life, except when the hernia is more than 1.5 cm, for which patient surgical repair is advised at 4-6 years of age (7, 10). The measurement of the hernia neck size in two dimensions and its description is necessary; moreover, the type and volume of hernia contents (such as fat, intestine, vessels) and whether the hernia is reducible should be mentioned since the possibility of strangulation of non-reducible (incarcerated) hernias is more likely (11). Nonetheless, the incarceration of the hernia is very uncommon. An ultrasound scan shows the underlying peritoneal contents that move freely during increased intra-abdominal pressure by the Valsalva maneuver or abdominal tingling in a normal umbilicus. In an umbilical hernia, the loop of the gas-filled intestine protrudes into the umbilical hernia as a superior umbilicus (Figures 1A & B).

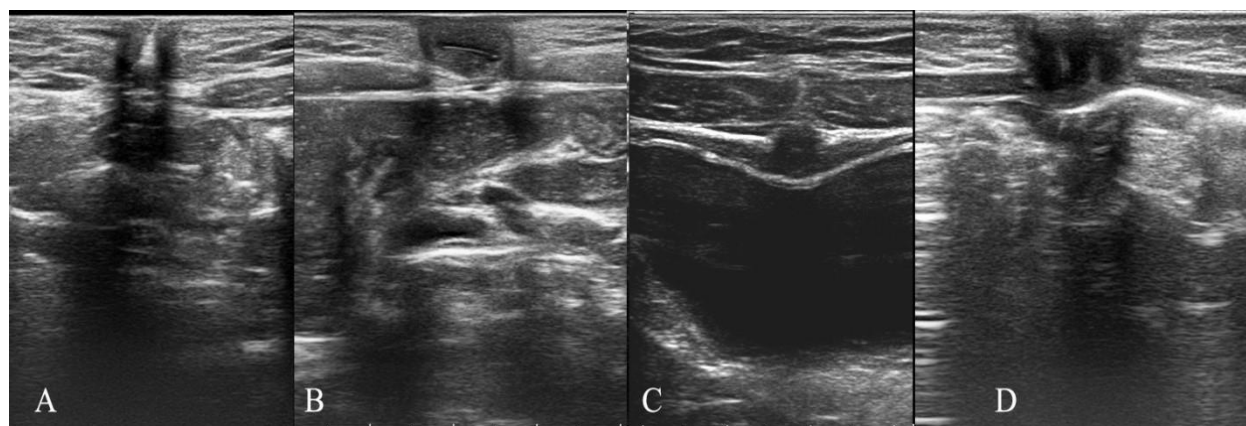


Figure 1. Four views of the normal umbilicus and related parts: A & B) The umbilical skin is seen as a mild hypoechoic dimple or ring. C) Normal urachal remnant in the anterosuperior surface of the urinary bladder (dome of the bladder) as an elliptical hypoechoic structure in the transverse view. D) Normal remnant of umbilical arteries as two echogenic bands

Masses

Although cord remnant, umbilical granuloma, and polyps of remnant enteric tissues are the main causes of umbilical masses, other masses may be found in the umbilicus, such as a fibrous umbilical polyp, skin tag, urachal polyp, lipoma, and others.

Umbilical Cord remnant

Clinically, the normal remnants of the umbilical cord form a central hump inside the umbilicus as an additional skin fold (1). The umbilical cord remnant is usually separated in the first month of life, and it is considered abnormal if

it persists after the end of the second month of life. Sometimes underlying abnormalities, such as immune disorders, can cause delayed separation; nonetheless, these cases are rare (12). We found no studies clarifying the ultrasound features of Umbilical Cord remnants in children. In our experience, the normal cord or its remnant was observed as a hypoechoic mass surrounded by an elevated skin ring during infancy. The collapsed vessels inside the cord are often seen as central echogenic dots or bands. The infected cord remnant (Omphalitis) may present as a large mass-like lesion with preserving cord echo texture. The abdominal extension of the cord remnant suggests a patent urachal or omphalomesenteric remnant. The cord remnant becomes completely hypo-echoic with aging. They are positioned deep in the umbilicus, starting from the parietal peritoneum with a broad base. The association of the umbilical granuloma with a normal cord remnant is also common, and differentiation of the normal cord remnant from other lesions is crucial (Figures 2B & C).

Umbilical granuloma

After umbilical hernia, the umbilical granuloma is the second most common umbilical problem. It is an inflammatory granulation mainly

caused by the delayed irregular separation of the cord stump. Failure in epithelialization and low-grade infection lead to discharge. This mass is the most common neonatal umbilical anomaly that presents as a pink or red mass lesion up to 1cm in size. When infected, these lesions are accompanied by swelling, tenderness, fever, or increased discharge (11). An umbilical granuloma is commonly treated with 75% silver nitrate sticks. Failure to respond to treatment with silver nitrate should raise suspicion of other abnormalities (5, 6). Surgical excision may be warranted for large pedunculated granulomas or those who do not respond to treatment (7, 8, 13). On ultrasound scans, typically, they appear as a hypoechoic nodule over the dome of the cord remnant or sac of the umbilical hernia. They are usually superficial solid nodules that are hypervascular in color Doppler ultrasound, although it has also been mentioned that hypervascularity can be suggestive of acute infection (11, 14). Hyper-echogenicity or severe hypo-echogenicity, heterogeneous echo-texture, deep or intra-peritoneal extension, and sinus track association suggest other lesions, such as cord, urachal, or omphalomesenteric duct remnant (6) (Figure 2D).

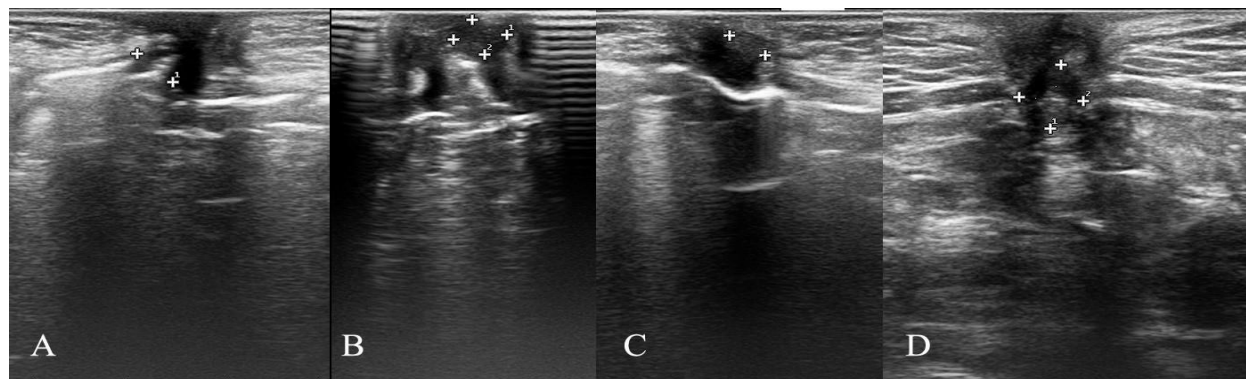


Figure 2. The umbilical masses: A) Umbilical hernia associated with umbilical cord remnant B) Umbilical hernia associated with umbilical granuloma C) umbilical cord remnant associated with umbilical granuloma D) Polyp of enteric tissue of omphalomesenteric duct remnant

Polyps

They are usually a small remnant of the enteric mucosa in the umbilicus. Urachal remnant polyps are sometimes observed presenting as an umbilical red mass or discharge in the neonatal period. The primary differential is umbilical granuloma (10, 15). These lesions do not respond to conservative treatments (silver nitrate) (13). Moreover, 30%-60% of patients are associated with an underlying omphalomesenteric duct anomaly that presents as fluid-filled cystic

contents with thick echogenic walls and hypervascularity in color Doppler ultrasound (14). On ultrasound scan images, umbilical polyps are deep-seated lesions with mixed or hyper-echoic echo texture that can help differentiate them from umbilical cord remnants or umbilical granulomas. The mucosal nature of these polyps may be responsible for their hyper-echogenicity.

Urachal Remnants

The connection between the fetal bladder and

the allantois is called the urachus. In fetal life, while the bladder moves into the pelvis, the urachus stretches and obliterates its lumen. It forms a fibrous band extending from the umbilicus to the bladder called the median

umbilical ligament. Sometimes, this obliteration does not happen completely and causes urachal remnants (16). The incomplete closure of the urachal duct may present with various forms of lesions (Figure 3).

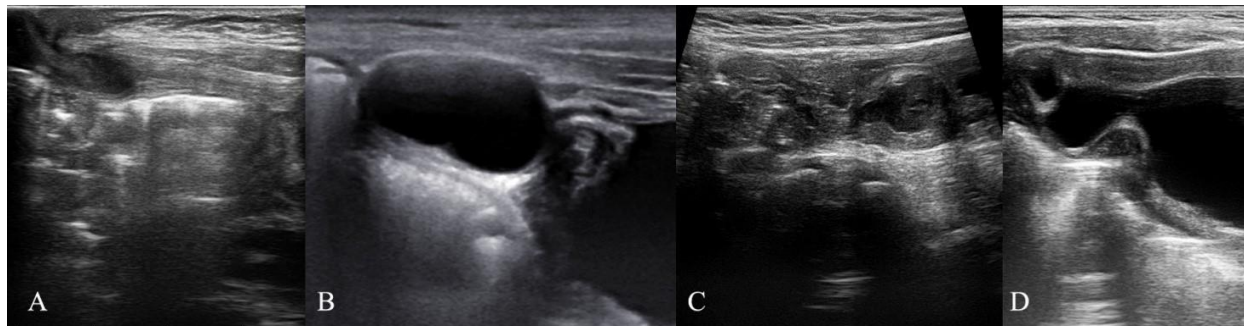


Figure 3. Different types of urachal remnant: A) sinus, B) cyst, C) patent, and D) diverticulum

Urachal Sinus

When urachus patent only at the umbilical-urachal sinus happens, it is an uncommon congenital lesion manifested as an umbilical mass or inflammation that can have drainage(3). The US can show a thickened irregular tubular structure with an echogenic center along the midline developing from the umbilicus without any communication to the urinary bladder (3, 17-20).

Urachal Cyst

Urachal cyst occurs if the umbilical and vesical ends of the urachus are obliterated, and the middle parts of the lumen remain open as a cystic lesion (19). Most patients are asymptomatic, and the diagnosis is usually suspected when they become symptomatic due to such complications as infection, which present as an abscess (3). In the US, an uncomplicated cyst can be diagnosed by demonstrating an extra-peritoneal thin-walled cyst, the midline between the umbilicus and the bladder (3, 18-20). The urachal abscess is formed as a tubular or oval-shaped collection. A collection at the midline in the lower abdominal wall associated with significant peripheral hyper-vascularity leads to the diagnosis of a urachal abscess (11, 21).

Patent Urachus or Urachal Fistula

Patent urachus, a fistula between the bladder and the umbilicus, is caused by a failure in the obliteration of the entire urachal duct leading to the discharge of urine. Some patients are asymptomatic. The prevalence of this anomaly is one in 200,000 live births (3). Although it may be treated by cauterization with silver nitrate, it

should be ligated surgically in persistent cases. On ultrasound scan, the demonstration of a tubular fluid-filled structure with a hypoechoic wall that communicates the anterosuperior aspect of the bladder and umbilicus is diagnostic. (18-20) General thickening of the urachus more than 4 mm, especially after infancy, indicates patent urachus. In infected patent urachus cases, urachal thickness is above 7 mm.

Urachal Diverticulum

If the urachus at the bladder end is not closed completely, the urachal diverticulum occurs, which causes an outpouching from the bladder dome at the location of the urachal attachment (3, 18). It is the rarest detected urachal abnormality, accounting for 3% of all urachal anomalies. This abnormality can be accompanied by prune belly syndrome in infants (19). On ultrasound scan, the Vesico-urachal diverticulum appears as an extra-luminally protruding, anechoic, and tubular fluid-filled sac arising from the bladder dome, not communicating or connecting with the umbilicus or the rest of the urachal tract (3, 17-20). The size of this tubular structure can change with bladder filling (20). Occasionally, an infected diverticulum presents as a mass-like lesion in the apex of the urinary bladder. Except for patent urachus, the other urachal lesions are usually asymptomatic until complicated by infection (21), and they might spontaneously disappear under one year of age (22). Infection is the most common complication of urachal anomalies (3). Surgical resection of the urachus is typically recommended in infected urachal

lesions since re-infection is common (11). Overall, surgical excision is recommended in symptomatic cases to prevent recurrent infections and the development of urachal adenocarcinoma (8).

Omphalomesenteric (vitelline) Duct Remnant

Similar to urachal remnant lesions, incomplete closure of the omphalomesenteric duct (OMD) (also known as the vitelline duct) may present in the umbilicus with several states (Figure 4).

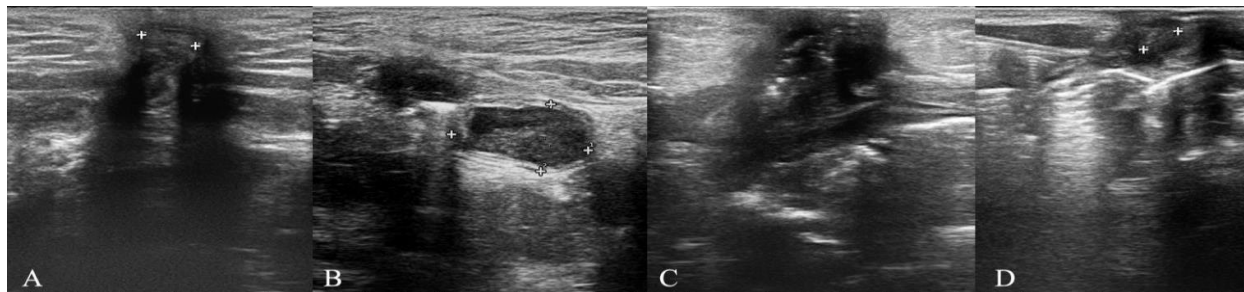


Figure 4. Different types of omphalomesenteric duct remnant: A) sinus and polyp, B) cyst, C) Patent, D) Band associated with polyp of enteric tissue

Vitelline Sinus

Vitelline sinus occurs due to failure in the obliteration of the distal part (umbilical portion) of the vitelline duct with atresia of the amount attached to the ileum; it presents with mucus discharge (23). No literature had identified the characteristics of vitelline sinus ultrasound findings. The multi-layered structure attached to the umbilicus was observed in one of our patients with an omphalomesenteric sinus.

Vitelline Cyst

A vitelline cyst forms when an intermediate portion of the OMD remains patent while the ends are obliterated. They are observed more commonly in boys. OMD cysts are typically asymptomatic, though they may be infected and present with firm, erythematous cystic swelling at the umbilicus. In abdominal ultrasound, they can be revealed as a multi-layered cystic lesion in the mid-abdomen close to the undersurface of the umbilicus (24). Enteric duplication cysts have a similar appearance; nonetheless, their lack of attachment to the abdominal wall is differentiating.

Patent Vitelline Duct or Fistula

Patent vitelline duct or fistula results in failure in the obliteration of the entire vitelline duct, leading to fecal discharge. We found two reports of patent vitelline duct in the literature, which referred to sonographic findings. In one paper, the ultrasound shows the communication of herniated small intestinal loops with the base of a protruding umbilical mass at the umbilicus (25).

Vitelline Band

The vitelline band is a fibrous band emerging

due to incomplete obliteration of the vitelline duct or the vitelline vessels that connect the intestine or mesentery to the umbilicus. This band can cause bowel obstruction or volvulus (21). The vitelline bands are demonstrated in the US as hyperechoic striated bands extending to the umbilicus. The obliterated duct or multi-layer nature of vessel and interface reflection cause hyperechoic lines on ultrasound. In complicated cases, the band is enveloped by edematous bowel or mesentery (26).

Meckel's Diverticulum

Meckel's diverticulum is caused by a failure in the obliteration of the bowel portion of the vitelline ducts that is usually found about 40-60 cm proximal to the ileocecal valve and may present with diverticulitis and misdiagnosed as appendicitis (27). Although of limited value, sonography is used to examine Meckel's diverticulum. On ultrasound, it usually appears as a fluid-filled tubular blind-ending structure in the right lower quadrant. It is a thick-walled loop with communication to a peristaltic, normal small-bowel loop of the bowel. Since its wall has all the layers of a normal bowel wall, hyperechoic mucosa ("gut signature sign") is always detected in ultrasound images. Enteroliths can also be detected as echogenic foci with posterior shadowing (28-30). By handling compression on it and expressing echo-free contents into the ileum, the connection between this fluid-filled structure and small bowel can be shown, which helps differentiate Meckel's diverticulum from enteric duplication cyst with an echogenic wall without any contact with the ileal lumen(31). In one study, the diagnostic value of a new sonographic sign, the pseudogestational sac

sign, in diagnosing Meckel diverticulum was assessed in children referred with rectal bleeding. It appears blind-ended cystic mass with a thick echogenic wall and clear or turbid content. It was demonstrated that the pseudogestational sac sign could be a valuable and reliable sonographic sign for diagnosing Meckel diverticulum in children referred with rectal bleeding (32).

The most common presentation of pediatric cases of omphalomesenteric duct remnants is an intestinal obstruction (5). The mechanisms of bowel obstruction include intussusception, volvulus, kinking of loops, adhesions, internal hernia, and diverticulitis (25, 26). The attachment

of the small bowel to the umbilicus was excluded by observing the free mobility of the underlying loops under the umbilicus (6). The multi-layered wall (gut signature) is easily observed in omphalomesenteric (vitelline) duct remnants, such as Meckel's diverticulum and vitelline sinus or cyst. Surgical excision is the treatment of choice for these lesions (10).

Inflammation

Dermatitis, Omphalitis, and Omphalophlebitis are three inflammatory lesions of the umbilicus (Figure 5).

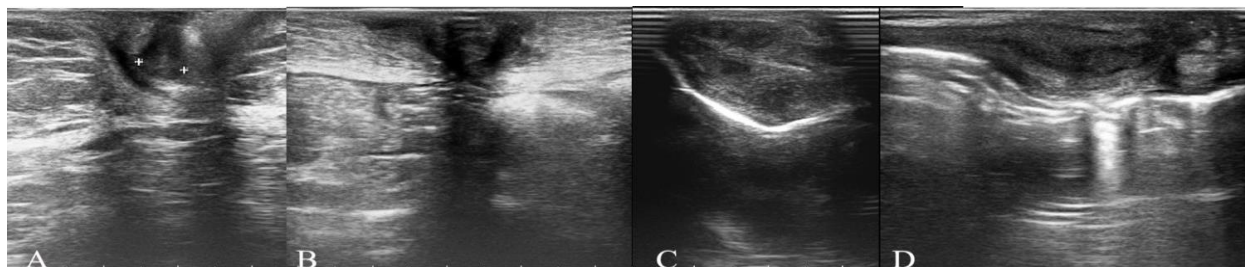


Figure 5. Umbilical inflammation: A) Umbilical granuloma associated with dermatitis B) Omphalitis and peri-umbilical cellulitis. C) Omphalitis as completely enlarged cord remnant D) Long axis view of omphalophlebitis: enlarged vein with intraluminal hyperechogenicity

Dermatitis is one of the common diseases of the umbilicus. Various types of dermatitis, such as atopic, contact, diaper, discharge, candida, and intertrigo dermatitis, occur in the umbilicus (33, 34). They present on ultrasound with the thickening of the dermal part of the umbilical skin ring.

Omphalitis is a rare bacterial infection of the umbilicus or surrounding tissues resulting from organisms colonized in this area (5). It starts with omphalitis and superficial peri-umbilical cellulitis (8) and may progress to necrotizing fasciitis, a rapidly life-threatening abdominal wall infection. This lesion should be treated aggressively with parenteral antibiotics and surgical excision (8, 10). Ultrasonographic findings of omphalitis or the infected cord remnant are enlarged umbilicus as a large mass-like lesion associated with edema peri-umbilical skin and subcutaneous tissues. Hypervascularity is noted in color Doppler ultrasound images (35).

Omphalophlebitis, or The infection of the umbilical vein, has been reported in the Veterinary field, and it has been classified with or without the involvement of the liver and even liver abscesses. A course of broad-spectrum antibiotic therapy is necessary for these patients (36, 37). One newborn presented with a discharging umbilical mass and was treated with

intravenous antibiotic therapy. On ultrasound, it is characterized by a disseminated increase in the size of the vein and its wall. The lumen of the umbilical vein will be distended with a heterogeneous hypoechoic clot. In animals, omphaloarteritis is characterized by the same ultrasonographic findings described for omphalophlebitis and asymmetry of the umbilical arteries.

Discussion

Umbilical lesions are common problems, including hernia, granuloma, cord abnormalities, Urachal lesions, Omphalomesenteric (vitelline) duct remnants, and vessels, in children. Clinically, the treatment of umbilical cord diseases is diverse. Some are uncomplicated and can be treated medically and conservatively, such as granulomas, uncomplicated urachal lesions, and dermatitis. Some require surgical treatment, such as omphalomesenteric malformations and complicated urachal lesions. Others are associated with complications and even death if not treated in time, such as omphalophlebitis, band-related volvulus, and omphalitis. Thereafter, differentiation and choice of medical or surgical treatment of umbilical cord lesions in children are vital. Moreover, this group of lesions usually has nonspecific clinical

manifestations, including discharge or swelling; it is difficult to distinguish and correctly diagnose them clinically. In addition, the concomitance of two umbilical lesions is common (8).

Nonetheless, imaging investigations can play a valuable role in differentiating these lesions. Today, ultrasound is used as an efficient technique to diagnose many pathologies due to its characteristics, including the high-resolution images, the absence of radiation, the possibility of performing it at the bedside, and its specific findings can even determine the best next diagnostic step. This review presents ultrasound findings of umbilical cord lesions in children. As illustrated in Table 1, their ultrasonographic diagnosis is straightforward due to the specific locations and features of the umbilical hernia and some urachal lesions. Nonetheless, the diagnosis of other lesions may be challenging. Umbilical cord remnants, granuloma, and polyps of the enteric remnant are the three main causes of umbilical nodules. However, different masses, such as fibrous umbilical polyps, skin tags, urachal polyps, and lipomas, may be found in the umbilicus.

The umbilical cord remnant and hernia are not required for treatment. Umbilical granuloma and other inflammatory lesions are treated medically, and infants with suspected umbilical polyps, omphalomesenteric ducts, and urachal remnants should be referred to pediatric surgeons for surgical evaluation (8). The umbilical cord remnant is presented as a deep, severe hypoechoic nodule with attachment to the peritoneum, while an umbilical granuloma is a superficial mild hypoechoic mass. Their hyper-echogenicity or heterogeneous echo texture, cystic component, deep-seated and trans-peritoneal extension suggest other lesions, such as omphalomesenteric duct remnant. Thereafter, ultrasound can help differentiate between granuloma and polyp of the enteric remnant. Differentiation in color Doppler ultrasound scan is that granuloma is usually hypervascular while a polyp of the enteric remnant is a hypovascular lesion (14). As mentioned above, the concomitance of umbilical lesions together is common. Therefore, a more detailed investigation is necessary to diagnose the underlying lesion in these patients.

It was noted that the vitelline cyst appears as a multi-layered cystic lesion in the mid-abdomen close to the undersurface of the umbilicus. Enteric duplication cysts have a similar appearance without attachment to the abdominal wall. In contrast, an uncomplicated urachal cyst shows an extra-peritoneal thin-walled cyst, the midline between the

umbilicus and bladder. In some patients, accompanying lesions, such as polyps, may be observed. Although dermatitis is a common and uncomplicated disease in the navel area, omphalitis is an aggressive disease that may be associated with complications. Peri-umbilical sub-cutaneous edema is indicated as omphalitis.

This review provides the ultrasound finding of umbilical lesions in children and insight into the fundamental features to be considered in ultrasound scans that may reliably distinguish and differentiate these lesions that can be important for adopting the correct diagnosis and treatment, planning surgery if needed, minimizing diagnostic errors, and decreasing the risk of associated complications.

This article has some limitations. A dearth of studies have investigated the ultrasound features of umbilical cord lesions in children. Few case-report and original papers describe the sonographic characteristics of several umbilical lesions. Therefore, presenting experiences and writing a review article about the differential characteristics of umbilical lesions in ultrasound have limitations. More studies, especially pathology-sonography correlation studies, are proposed to understand umbilical cord lesions better. The selection of suitable patients for medical treatment and follow-up based on ultrasound findings also requires more extensive research.

Conclusion

In conclusion, different types of umbilical lesions in children, including masses, cysts, sinuses, fistulas, and thrombosis, must be differentiated to receive medically appropriate treatment until immediate surgery. With the increasing use of ultrasound as an imaging modality for the detection of different pathologies, Ultrasound examination can be used as a valuable complementary assessment tool for experienced clinicians, allowing for the assessment of umbilical lesions and differentiating them and choosing the correct approach to the treatment of these lesions.

Acknowledgments

None.

Conflicts of interest

The authors declare that they have no conflict of interest.

References

- Fahmy M. Anatomy and physiology of the umbilicus. *Umbilicus and Umbilical Cord*: Springer; 2018.
- Das A. Umbilical lesions: a cluster of known unknowns and unknown unknowns. *Cureus*. 2019; 11(8):e5309.
- Khati NJ, Enquist EG, Javitt MC. Imaging of the umbilicus and periumbilical region. *Radiographics*. 1998; 18(2):413-31.
- Campbell J, Beasley SW, McMullin N, Hutson JM. Clinical diagnosis of umbilical swellings and discharges in children. *Med J Aust*. 1986; 145(9):450-3.
- Pomeranz A. Anomalies, abnormalities, and care of the umbilicus. *Pediatr Clin N Am*. 2004; 51(3):819-27.
- Boothroyd A, Cudmore R. Ultrasound of the discharging umbilicus. *Pediatr radiol*. 1996; 26(5):362-4.
- Hegazy AA. Anatomy and embryology of umbilicus in newborns: a review and clinical correlations. *Front Med*. 2016; 10(3):271-7.
- Muniraman H, Sardesai T, Sardesai S. Disorders of the umbilical cord. *Pediatr Rev*. 2018; 39(7):332-41.
- Olthof DC, Reemst S, Sleeboom C, Kuijper C, van Schuppen J, Derikx J, et al. Diagnostic accuracy of abdominal ultrasound to detect pathology that needs surgical exploration in children with umbilical discharge. *J Pediatr Surg*. 2021; 56(8):1436-40.
- Poenaru D. Disorders of the umbilicus in infants and children: A consensus statement of the Canadian Association of Paediatric Surgeons. *Paediatr Child Health*. 2001; 6(6):312-3.
- Bansal AG, Rosenberg HK. Sonography of pediatric superficial lumps and bumps: illustrative examples from head to toe. *Pediatr Radiol*. 2017; 47(9):1171-83.
- Snyder CL. Current management of umbilical abnormalities and related anomalies. *Seminars in Pediatric Surgery*; 2007.
- Gaopande VL, Deshmukh SD, Khandeparkar SG, Suryavanshi MA, Patil VR. Clinical and histopathological profile of lesions of umbilicus. *Med J Dr DY Patil Univ*. 2015; 8(2):179.
- Kim DH, Lee HJ, Kim JY, Jung HR. Differential diagnosis of umbilical polyps and granulomas in children: sonographic and pathologic correlations. *Ultrasonography*. 2021; 40(2):248.
- Stock N, Azzis O, Jouan H. Umbilical polyp in an infant. *Pediatr Dev Pathol*. 2008; 11(2):165-6.
- Orbatu D, Alaygut D. Evaluation and management of urachal remnants in children. *Pediatr Int*. 2020; 62(10):1158-61.
- Yu JS, Kim KW, Lee HJ, Lee YJ, Yoon CS, Kim MJ. Urachal remnant diseases: spectrum of CT and US findings. *Radiographics*. 2001; 21(2):451-61.
- Parada Villavicencio C, Adam SZ, Nikolaidis P, Yaghmai V, Miller FH. Imaging of the urachus: anomalies, complications, and mimics. *Radiographics*. 2016; 36(7):2049-63.
- Buddha S, Menias CO, Katabathina VS. Imaging of urachal anomalies. *Abdom Radiol*. 2019; 44(12):3978-89.
- Luo X, Lin J, Du L, Wu R, Li Z. Ultrasound findings of urachal anomalies. A series of interesting cases. *Med Ultrason*. 2019; 21(3):294-8.
- Wan YL, Lee TY, Tsai CC, Chen SMS, Chou FF. The role of sonography in the diagnosis and management of urachal abscesses. *J Clin Ultrasound*. 1991; 19(4):203-8.
- Ueno T, Hashimoto H, Yokoyama H, Ito M, Kouda K, Kanamaru H. Urachal anomalies: ultrasonography and management. *J Pediatr Surg*. 2003; 38(8):1203-7.
- Bagade S, Khanna G. Imaging of omphalomesenteric duct remnants and related pathologies in children. *Curr Probl Diagn Radiol*. 2015; 44(3):246-55.
- Bahrami-Motlagh H, Sadeghi M, Amerifar M, Sabeti S, Rezaee SP, Peyvandi H. Concurrent omphalomesenteric duct cyst and ileal diverticulum causing small bowel obstruction; a case report. *Int J Surg Case Rep*. 2022; 94:107004.
- Taranath A, Lam A. Ultrasonographic demonstration of a type 1 omphalomesenteric duct remnant. *Acta Radiol*. 2006; 47(1):100-2.
- Sun C, Hu X, Huang L. Intestinal obstruction due to congenital bands from vitelline remnants: sonographic features and review of the literature. *J Ultrasound Med*. 2012; 31(12):2035-8.
- DiSantis D, Siegel M, Katz M. Simplified approach to umbilical remnant abnormalities. *Radiographics*. 1991; 11(1):59-66.
- Elsayes KM, Menias CO, Harvin HJ, Francis IR. Imaging manifestations of Meckel's diverticulum. *AJR Am J Roentgenol*. 2007; 189(1):81-8.
- Dames EL, Hamouda ES. Radiologic imaging in meckel diverticulum complications. *J Med Ultrasound*. 2015; 23(3):133-41.
- Alamdaran SA, Taherinezhad M, Feyzi A. Ileum terminal and mesenteric vessels; two fundamental gateways of ultrasound examination in acute abdomen of children. *Int J Pediatr*. 2021; 9(8):14183-95.
- Kotha V, Khandelwal A, Saboo S, Shanbhogue A, Virmani V, Marginean E, et al. Radiologist's perspective for the Meckel's diverticulum and its complications. *Br J Radiol*. 2014; 87(1036):20130743.
- El-Maadawy SM, Alaaeldin N, Zefov VN. Value of sonographic pseudogestational sac sign in the diagnosis of Meckel diverticulum in children presenting with bleeding per rectum: a 15-year prospective study. *Egypt J Radiol Nucl Med*. 2021; 52(1):1-12.
- Migoto MT, de Souza SNDH, Rossetto EG. Skin lesions of newborns in a neonatal unit: descriptive study. *Online Braz J Nurs*. 2013; 12(2):377-92.
- Sezer A, Toprak D. Skin lesion on umbilical region. *Euras J Fam Med*. 2013; 2(2):95-9.
- Lee K, Jo H, Jeon E, Jung K, Moon J, Park S. Omphalitis in neonates and infants: imaging findings and

- assessment of underlying causes using sonography. Radiological Society of North America; 2012.
36. Steiner A, Lejeune B. Ultrasonographic assessment of umbilical disorders. *Vet Clin North Am Food Anim Pract.* 2009; 25(3):781-94.
37. Franklin RP, Ferrell EA. How to perform umbilical sonograms in the neonate. *InProc Am Assoc Equine Pract;* 2002.