

Effect of Hemodynamic Significant Patent Ductus Arteriosus on Tissue Oxygenation in Preterm Infants using Near-Infrared Spectroscopy

Martono Tri Utomo^{1*}, Risa Etika¹, Mahrus Abdul Rahman¹, Mahendra Tri Arif Sampoerna¹, Sunny Mariana Samosir¹

1. Child Health Department, Faculty of Medicine, Airlangga University, Jawa Timur, Indonesia, and Dr. Soetomo General Academic Hospital, Surabaya, Indonesia

ABSTRACT

Background: Hemodynamic significant Patent Ductus Arteriosus (hsPDA) is one of the main complications of preterm birth; however, its management needs further research and development. Ductal stealing results in pulmonary hyperperfusion which potentially causes oxygenation disorders and leads to target organ disruptions (i.e. cerebral, abdominal, and renal). Therefore, monitoring tissue oxygenation is essential for detecting organ disorders. Previous studies revealed that near-infrared spectroscopy (NIRS), as a non-invasive method, showed promising results in monitoring tissue oxygenation. This study aimed to analyze the difference in regional oxygen saturation (rSO₂) between premature babies with and without hsPDA.

Methods: This cross-sectional study was conducted on preterm infants aged 3-7 days with 24-336/7 weeks of gestation. hsPDA diagnosis was carried out using echocardiography; defined as >1.5 mm diameter of ductus arteriosus and >1.4 left pulmonary artery and aorta (La/Ao) ratio. The cerebral (rcSO₂), abdomen (raSO₂), and renal oxygen saturation (rrSO₂) were measured through NIRS monitoring. The statistical analysis was conducted using SPSS software (Version 21.0).

Results: There were 11 out of 52 infants categorized as hsPDA. The mean±SD birth weight, mean±SD gestational age, and mean±SD ductus diameter in hsPDA was determined at 1213±293 gram; 30.72±2.01 weeks, and 2.84±0.93 mm, respectively. There was no significant difference between the hsPDA and non hsPDA groups in terms of rcSO₂ (75.27±9.14% and 79.03±9.11%; P=0.238), raSO₂ (65.60±11.07% and 67.48±10.17%; P=0.594), and rrSO₂ (76.41±14.98% and 82.61±10.41%; P=0.218).

Conclusion: Based on the obtained results, the existence of hsPDA doesn't affect the oxygenation in cerebral, abdominal, and renal tissues in preterm babies. Moreover, the decision should be made regarding the optimal time for ductal closure.

Keywords: Hemodynamic significant patent ductus arteriosus, Near-infrared spectroscopy, Preterm infant

Introduction

Ductus arteriosus (DA) will normally shrink after birth in term infants and is functionally closed 72 h postnatal. The ductal closure is delayed until 4 days of age in 10%, 80%, and 90% of preterm babies born at gestational age 30-37 weeks, 25-28 weeks, and <24 weeks(1,2). Persistent DA can cause hemodynamic significant Patent Ductus Arteriosus (hsPDA) in which the systemic shunt to the pulmonary vessels results

in pulmonary hyperperfusion and systemic hypoperfusion(3). Therefore, understanding tissue perfusion and oxygenation is an important consideration for the administration of ductal closure in premature infants to avoid further morbidity and mortality(4-6). The ductal shunting from systemic to pulmonary blood flow has an impact on the cerebral, abdominal, and renal circulation(7). Uncorrected hsPDA can

* Corresponding author: Martono Tri Utomo, Neonatology Division, Child Health Department, Faculty of Medicine, Airlangga University, Jawa Timur, Indonesia. Email: mrmartono73@gmail.com

Please cite this paper as:

Tri Utomo M, Etika R, A. Rahman M, Tri Arif Sampoerna M, Mariana Samosir S. Effect of Hemodynamic Significant Patent Ductus Arteriosus on Tissue Oxygenation in Preterm Infants Using Near-Infrared Spectroscopy. Iranian Journal of Neonatology. 2022 Jan; 13(1). DOI: [10.22038/IJN.2022.55757.2040](https://doi.org/10.22038/IJN.2022.55757.2040)

cause intraventricular hemorrhage, necrotizing enterocolitis (NEC), and renal insufficiency(6). The long-term impact of decreased cerebral oxygenation in infants less than one-month-old includes brain damage and development disorders(8).

Clinical assessment and echocardiography have become reliable methods of diagnosing hsPDA. Near-Infrared Spectroscopy (NIRS) has been validated as a non-invasive tool to measure regional oxygen saturation (rSO₂) that can detect early changes in organ perfusion and oxygenation and help identify and monitor the hsPDA therapy(9). A study conducted by van der Laan showed that cerebral and renal oxygenation is not affected by hsPDA.(6) However, the results of a study performed by Lemmers et al. and Cohen et al. proved negative effects of hsPDA on cerebral oxygenation in premature infants(8,10). There have been many studies on regional perfusion and oxygenation in premature infants with NIRS(8-10). However, to the best of the researcher's knowledge, there have not been enough studies on differences in regional oxygenation, especially in preterm infants using NIRS, in Indonesia.

The present study aimed to study differences in regional tissue oxygenation in preterm infants with hemodynamic significant and non-hemodynamic significant Patent Ductus Arteriosus using NIRS in the early days of life in preterm babies.

Methods

Patients

This cross-sectional study was conducted on 52 out of 191 preterm infants treated in the NICU during the study period. The sampling was performed using a consecutive sampling technique. All preterm babies (with gestational age 24-33 weeks) were born between November 2019 and May 2020 at the tertiary level neonatal intensive care unit (NICU) of Dr. Soetomo General Hospital in Surabaya, Indonesia. This hospital possessed oxygen support devices (i.e. high flow nasal cannula, continuous positive airway pressure, invasive and non-invasive ventilator) that met the inclusion criteria in this study. Patients with multiple congenital anomalies, ductal dependent cyanotic heart defects, early onset of septicemia, and no consent from parents were excluded from the study. Demographic and clinical data were collected from the medical records. The sample size was calculated using a formula for continuous data (hsPDA and non hsPDA). The ratio of samples between two groups

was based on the previous study.¹¹

Echocardiography

Echocardiography screening was performed between the days 3 and 7 postnatal by the pediatric cardiology consultant, using S9 Sonoscape Portable Digital Color Doppler Ultrasound System (SonoScape, Shenzhen). Echocardiography was performed by one pediatric cardiology consultant to minimize the performance variability. The samples were categorized into two groups of hsPDA and non hsPDA. The hsPDA was considered to exist if there was a ductus arteriosus with diameter >1.5 mm on constriction phase, left pulmonary artery diameter and aorta diameter ratio (LA/Ao) was >1.4, and left to right shunt was present. However, the already closed DA that did not fulfill the requirement for hsPDA was considered to be non-hsPDA.

NIRS Measurements

INVOS 5100C near-infrared spectrometer and neonatal sensors (Covidien, USA) were used to monitor the tissue oxygen saturation on the day echocardiography was performed. Multisite sensors were placed on the frontoparietal side of the infant's head, inferior side of the umbilicus, and the lateral posterior flank to evaluate the cerebral tissue oxygen saturation (rcSO₂), the abdominal tissue oxygen saturation (raSO₂), and the renal oxygen saturation (rrSO₂), respectively. The evaluation was performed by different examiners who were unaware of the echocardiography result. The oxygen saturation changes were observed for 15 min continuously. The machine records tissue oxygen saturation data every 15 sec. Mean regional rSO₂ was used for further analysis. A pulse oximeter was also put on the baby's right hand to evaluate the peripheral oxygen saturation (spO₂) for further calculation of fractional tissue oxygen extraction (FTOE) on each location using the following formula: $FTOE = (spO_2 - rSO_2) / spO_2$. A 15-min measurement was simultaneously observed and the mean values were obtained as well.

Statistical Analysis

Differences in clinical characteristics of the two groups of hsPDA and non hsPDA were analyzed using Chi-square test, Fisher's exact test, and Fisher's exact probability test. Statistical analyses of the difference in regional oxygen saturation and fractional tissue oxygen extraction between both groups were performed using independent t-test and Mann Whitney test. Moreover, logistic

regression analysis showed no significant relationship between hsPDA and non hsPDA groups. Statistical analysis was conducted using SPSS software (Version 21.0). A p-value less than 0.05 ($P < 0.05$) was considered statistically significant.

Ethics

The ethical approval was issued by the Ethical Committee of Dr. Soetomo General Hospital, Surabaya, Indonesia (No.1766/105/XI/2019).

Results

In this study, three babies had multiple congenital anomalies, four babies had early onset of septicemia, and the others were excluded due to incomplete data and lack of written informed consent. In this study, 11 infants were classified as hsPDA group based on echocardiography results. There were 25 (48%) and 27 (52%) preterm male and female infants, respectively. A majority (55.8%) of the patients were in 28-<32 weeks of gestational age, and the mean gestational age was determined at 30.72 ± 2 weeks and 30.78 ± 2 weeks for hsPDA and non hsPDA groups, respectively. The mean \pm SD birth weight for patients in hsPDA

and non hsPDA groups was estimated at 1213 ± 293 and 1272 ± 306 grams, respectively.

Table 1 presents the neonatal characteristics of both study groups. There was no significant difference among variables; therefore, the samples were considered homogenous.

Based on the obtained results, the smallest and the largest DA diameter in the hsPDA group were 1.5 mm and 4.8 mm, respectively. The mean \pm SD duct diameter in the hsPDA group ($n=11$) was obtained at 2.84 ± 0.93 . The mean \pm SD of LA:Ao ratio was obtained at 1.56 ± 0.26 . The mean \pm DSD ejection fraction in hsPDA and non hsPDA groups was determined at 71.55 ± 5.72 and $73.94 \pm 9.4\%$, respectively.

Linear regression was used to evaluate patients' comorbidities (i.e., perinatal asphyxia, respiratory distress syndrome, and persistent pulmonary hypertension) as confounding factors for the estimation of regional oxygen saturation. All the observed differences were not significant. There were no significant differences between hsPDA and non hsPDA groups ($P=0.238$, $P=0.598$, and $P=0.218$, respectively) in terms of the tissue oxygen saturation ratio of cerebral (rcSO₂),

Table 1. Characteristics of participants

	hsPDA n (11)	non-hsPDA n (41)	Total n (52)	P
Gender				
Male	5 (9.6)	20 (38.5)	25 (48.1)	1.000*
Female	6 (11.5)	21 (40.4)	27 (51.9)	
Gestational age				
Extremely Preterm (<28 weeks)	1 (1.9)	3 (5.8)	4 (7.7)	1.000**
Very Preterm (28 - <32 weeks)	6 (11.5)	23 (44.3)	29 (55.8)	
Moderate Late Preterm (32 - <37 weeks)	4 (7.7)	15 (28.8)	19 (36.5)	
Birth weight				
ELBW (<1000 g)	2 (3.9)	6 (11.5)	8 (15.4)	0.902**
VLBW (<1500 g)	7 (13.5)	24 (46.1)	31 (59.6)	
LBW (<2500 g)	2 (3.9)	11 (21.1)	13 (25)	
Singleton/multiple birth				
Singleton	11 (21.1)	35 (67.4)	46 (78.5)	0.322
Multiple birth	0 (0.0)	6 (11.5)	6 (11.5)	
Respiratory support				
High flow nasal cannula	1 (1.9)	1 (1.9)	2 (3.8)	0.474**
CPAP	7 (13.5)	33 (63.5)	40 (77)	
Non invasive ventilator	1 (1.9)	1 (1.9)	2 (3.8)	
Invasive ventilator	2 (3.9)	6 (11.5)	8 (15.4)	
HR (x/minute), mean \pm SD	165 \pm 14.4	148 \pm 10.5		
SpO ₂ (%), mean \pm SD	97.1 \pm 2.7	97.0 \pm 1.9		
Hb, mean \pm SD	15.73 \pm 3.46	15.37 \pm 2.58		0.702
Inotropes				
No	8 (15.4)	38 (73.1)	46 (88.5)	0.101
Yes	3 (5.7)	3 (5.7)	6 (11.5)	
Age during recruitment				
3 day	3 (5.7)	21 (40.5)	24 (46.2)	0.118
4 day	6 (11.5)	10 (19.3)	16 (30.8)	
5 day	1 (1.9)	5 (9.6)	6 (11.5)	
6 day	1 (1.9)	4 (7.7)	5 (9.6)	
7 day	0 (0.0)	1 (1.9)	1 (1.9)	

Table1. Continued

Infant's comorbidity				
Respiratory distress syndrome	6 (11.5)	12 (23.1)	18 (34.6)	0.086
Perinatal Asphyxia	2 (3.8)	11 (21.1)	13 (24.9)	
PPHN	3 (5.7)	3 (5.7)	6 (11.4)	
Hyperbilirubinemia	4 (7.7)	6 (11.5)	10 (19.2)	
Others	1 (1.9)	9 (17.3)	10 (19.2)	
APGAR score in 5 min				
≤5	6 (11.5)	19 (36.5)	25 (48)	0.886*
>5	5 (9.6)	22 (42.4)	27 (52)	
Mode of delivery				
SC with general anesthesia	6 (11.5)	7 (13.5)	13 (25)	0.094**
SC with regional anesthesia	3 (5.7)	19 (36.5)	22 (42.2)	
Spontaneous birth	2 (3.8)	14 (27.0)	16 (30.7)	
Assisted vaginal birth	0 (0.0)	1 (1.9)	1 (1.9)	
Amniotic fluid				
Clear	10 (19.3)	38 (73.1)	(92.4)	0.134**
Turbid	1 (1.9)	0 (0.0)	(1.9)	
Meconium	0 (0.0)	3 (5.7)	(5.7)	
Mother's comorbidity				
Healthy	1 (1.9)	2 (3.8)	3 (5.7)	0.357**
Hypertension	6 (11.5)	11 (21.1)	17 (32.7)	
Obesity	0 (0.0)	2 (3.8)	2 (3.8)	
Antenatal bleeding	1 (1.9)	1 (1.9)	2 (3.8)	
Combination of 2	1 (1.9)	14 (26.9)	15 (28.8)	
Combination of 3	2 (3.8)	9 (17.3)	11 (21.1)	
Others	0 (0.0)	2 (3.8)	2 (3.8)	
Antenatal corticosteroid				
No	7 (13.5)	27 (52)	34 (65.5)	1.000
Yes	4 (7.7)	14 (26.8)	18 (34.5)	

Table 2. Comparison of regional oxygen saturation and fractional oxygen extraction in hsPDA and non hsPDA groups

	hsPDA		Non hs-PDA		P-value
	(n)	(mean±SD)	(n)	(mean±SD)	
r _c SO ₂	11	75.27±9.14	41	79.03±9.11	0.238
r _a SO ₂	11	65.60±11.07	41	67.48±10.17	0.594
r _c SO ₂	11	76.41±14.98	41	82.61±10.41	0.218
cFTOE	11	0.22±0.09	41	0.19±0.08	0.473
aFTOE	11	0.33±0.11	41	0.30±0.10	0.578
rFTOE	11	0.26±0.19	41	0.16±0.12	0.151

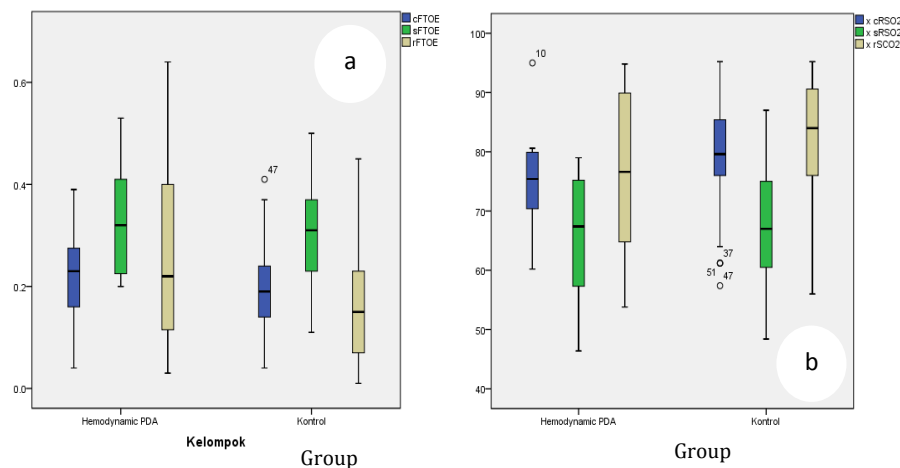


Figure 1a. Box plot diagram of regional FTOE values in the hsPDA and non hsPDA groups

Figure 1b. Box plot diagram of regional rSO₂ values in the hsPDA and non hsPDA group

abdominal (raSO₂), or renal (rrSO₂) areas (Table 2). No significant differences were observed in fractional oxygen extraction in cerebral (cFTOE), abdominal (aFTOE), and renal (rFTOE) areas

between hsPDA and non hsPDA groups (P=0.473, P=0.578, and P=0.151, respectively).

Discussion

The obtained results indicated that there

were no significant differences between the characteristics of the two study groups. Based on the evidence, the incidence of hsPDA increases with lower oxygen saturation(12). The mean SpO₂ in this study was around 97% with a low setting of CPAP (positive end expiratory pressure less than 7 and oxygen fraction less than 40%) and mechanical ventilation. In addition, there were no significant differences between the hsPDA and non hsPDA groups in terms of rcSO₂ (P=0.238). In the same line, the results of an observational cohort design study performed by van der Laan et al. in the Netherland revealed that oxygen saturation and oxygen extraction in cerebral and renal tissues of preterm infants (n=49) with gestational age<32 weeks evaluated by NIRS were not affected by the hsPDA.(6) The rcSO₂ level in the hsPDA group (69%) was lower than the non hsPDA group (76%), and cFTOE was higher in the hsPDA group (0.22), compared to non hsPDA group (0.33).

In contrast to the results of several previous studies in which a decrease in cerebral oxygenation was found in the hsPDA patients, Lemmers et al. reported a lower rcSO₂ level in infants with hsPDA group, compared to the asymptomatic PDA group (62±9% and 72±10%, respectively). however, the difference might be caused by several factors affecting the patient's hemodynamics. In Lemmers' study, the patients in hsPDA group used ventilators, morphine (as a sedative that causes peripheral vasodilation), and inotropic dopamine more than patients in the group of control. Dopamine administration can increase cardiac output which affect perfusion. In addition, the sampling was carried out earlier (in the first 72 h) in the Prescott's study, compared to the present study (3-7 days postnatal) which could have affected the results of the measured oxygenation level. It is agreed that the cerebral oxygen supply in infants increases with age. Based on the evidence, FTOE was also significantly higher in premature infants with hsPDA than those with non hsPDA(13). The relationship between oxygen transport (DO₂) and tissue oxygen consumption (VO₂) is fractional tissue oxygen extraction (FTOE=VO₂/DO₂). A negative correlation between rcRSO₂ and cFTOE indicates that a decrease in the brain oxygen supply in sick premature babies increases the cerebral oxygen extraction to maintain oxygen availability in the brain(14).

The results of a retrospective study by Chock et al. showed that a low rcSO₂ level (<66%) was associated with the presence of hsPDA in preterm

infants(9). Although the oxygenation value in cerebral tissue of hsPDA infants was lower than that in non hsPDA infants, the mean value was still higher compared to the cerebral oxygen saturation limit (<40%) associated with the appearance of such symptoms as ischemic lesions and neuron damage. The normal value of rcSO₂ for preterm babies is 55-85%(15). According to Dix et al., higher rcSO₂ values in neonatal sensors compared to adult NIRS sensors might be caused by differences in the NIRS signal reception process in which the neonatal NIRS sensor algorithm was adjusted to thinner neonatal calvarium to facilitate the light entrance(16).

Although the decision "to treat or not to treat" is still a clinical question nowadays, Poon et al. reported an improvement in cFTOE after medical therapy and PDA ligation(17). Clinical observations using NIRS provide a continuous monitoring on PDA closure and cerebral hypoxia, which can help clinicians evaluate the infants. It is necessary to identify infants at high risk of long-term developmental disorders.

Although not statistically significant (P=0.594), raSO₂ level was lower in premature infants with hsPDA than non hsPDA (65.60±11.07 and 67.48±10.17, respectively). Similarly, abdominal fractional oxygen extraction in infants with and without hsPDA was determined at 0.33±0.11 and 0.3±0.1, respectively (P=0.578). These findings were similar to the results of a study by Petrova et al., in which no significant difference was found between tissue oxygen saturation in cerebral, abdominal, and renal tissues of preterm infants at a gestational age of <32 weeks with a PDA diameter of ≥3, compared to <3 mm(18). Similarly, Gorman et al. found no statistical difference in hsPDA infants who were given ibuprofen therapy and those who were not. (19) It was reported that NIRS facilitated benefits by showing a downward trend of 20% of the baseline value of oxygen saturation before the appearance of clinical manifestation of NEC. In the present study, three preterm infants with hsPDA and seven infants with non-hsPDA experienced NEC, based on Bell stage criteria.

The results of an observational prospective study conducted by Ledo et al. on 72 premature infants revealed that infants with hsPDA had significantly lower abdominal tissue oxygen saturation(20). Lower blood pressure and lower mesenteric oxygenation were obtained with increased oxygen extraction in tissues. Continuous monitoring of abdominal oxygenation needs to be done in newborns in whom a transition of the

gastrointestinal tract from a relatively dormant organ to the main area of nutrient absorption requires sufficient oxygen supply. Unlike cerebral circulation that has an autoregulation protection mechanism, mesenteric circulation in the abdomen cannot auto-regulate which leads to an increased risk of gastrointestinal hypoxia. Ledo et al. stated that hsPDA babies had lower blood pressure with lower abdominal oxygenation. An increase in abdominal FTOE was also observed in the first five days and stabilized on the 6th day postnatal. The aFTOE was also stabilized on the 6th day along with the spontaneous closure of the DA. In a previous study, babies with high catecholamine were excluded to minimize the confounding factors affecting oxygenation(20,21). NIRS somatic sensors placed in the abdominal region were expected to detect oxygenation disturbances in the abdomen. Abdominal oxygen saturation (raSO₂) depicts blood flow in the mesenteric artery as the main vascular supplier of the gastrointestinal tract(22).

In this study, there was no significant difference between the groups of hsPDA and non hsPDA patients ($P=0.218$), in terms of rrSO₂ value (76.41 ± 14.98 and 82.61 ± 10.41 , respectively). Normal rrSO₂ in premature babies is 80%. The average rrSO₂ score in newborns is 40% that increases to 80-90% within 10 min and then decreases with the improvement of renal blood flow which increases the utilization of oxygen in the kidneys¹⁸. In a cohort study of premature infants in the first week of life, it was found that rrSO₂<66% was associated with the presence of hsPDA, based on echocardiography criteria with a sensitivity of 81% and specificity of 77%. The difference could be due to the fact that in the previous study, ventilators were used for the babies whose rrSO₂ was <66% and weighted <1000 grams. Low rrSO₂ values can be caused by immature renal function or hemodynamic instability other than PDA(9). Guzoglu et al. reported no significant difference in the regional oxygen saturation of the kidneys with rrSO₂ value of 60% (in the range of 17-93%, $P=0.87$) and rFTOE value of 0.37 (in the range of 0.06-0.83, $P=0.87$) in infants with hsPDA and controls (6,22,23). The rrSO₂ value obtained in the present study was relatively higher than that obtained in other studies. This might be due to renal NIRS monitoring conducted on days 3 to 7 post-natal when oxygen perfusion and utilization in the kidneys were still in the transition process.

This study provided valuable information about oxygen saturation in three body regions in

both groups, simultaneously. However, regarding the limitations of the present study, one can refer to the fact that NIRS measurement of tissue oxygen saturation was only performed in a short period of time. Therefore, there is a need for a longitudinal study to evaluate oxygen saturation trends. Moreover, tissue oxygen saturation assessment in this study has been based on NIRS monitoring alone and was not confirmed by other supporting examinations. Eventually, the sample size was small due to time limitations.

Conclusion

The results of the present study suggested that hsPDA did not affect oxygenation in cerebral, abdominal, and renal tissues in preterm infants during the examination. The decision should be made regarding the optimal time for ductal closure. Eventually, further large-scale studies should be conducted to reassess the obtained results in the present study.

Acknowledgment

The authors wish to thank the director of Dr. Soetomo Hospital, Surabaya, Indonesia, for the ethical approval of the study and endless supports.

Authors' contribution

Martono Tri Utomo, Sunny Mariana Samosir, and Mahrus A. Rahman designed and conducted the initial analysis. Risa Etika, Martono Tri Utomo, Dina Angelika, Kartika D. Handayani, and Mahendra T.A.S. worked together as the neonatologists in charge of the NICU. Rahman performed the echocardiography examination in all patients. Samosir collected the NIRS data, conducted further analysis, and drafted the manuscript. All authors had read and approved the final version of the manuscript.

Conflict of interest

The authors have no conflict of interest regarding the publication of the present study.

References

1. Benitz WE. Patent Ductus Arteriosus in Preterm Infants. *Pediatrics*.2016;137(1).
2. Hung Y, Yeh J, Hsu J. Molecular Mechanisms for Regulating Postnatal Ductus Arteriosus Closure. *Int J Mol Sci*. 2018;19:1861.
3. Harkin P, Marttila R, Pokka T, Saarela T, Hallman M. Morbidities Associated with Patent Ductus Arteriosus in Preterm Infants. *Nationwide Cohort Study*. *J Matern Fetal Neonatal Med*. 2018;31:2576-2583.

4. Breatnach CR, Franklin O, McCallion N, El-Khuffash A. The Effect of a Significant Patent Ductus Arteriosus on Doppler Flow Patterns of Preductal Vessels: An Assessment of the Brachiocephalic Artery. *J Pediatr*. 2017;180:279-281.
5. Sallmon H, Koehne P, Hansmann G. Recent Advances in the Treatment of Preterm Newborn Infants with Patent Ductus Arteriosus. *Clin Perinatol*. 2016; 43(1):113-129.
6. Van der Laan ME, Roofthoof MTR, Fries MWA, Berger RMF, SchatTE, van Zoonen AGJF, Tanis JC, Bos AF, et al. A Hemodynamically Significant Patent Ductus Arteriosus Does Not Affect Cerebral or Renal Tissue Oxygenation in Preterm Infants. *Neonatology*. 2016;110(2):141-147.
7. Kindler A, Seipolt B, Heilmann A, Range U, Rudiger M, Hofmann SR, et al. Development of a Diagnostic Clinical Score for Hemodynamically Significant Patent Ductus Arteriosus. *Front Pediatr*. 2017;5:280.
8. Cohen E, Dix L, Baerts W, Alderliesten T, Lemmers P, van Bel F. Reduction in Cerebral Oxygenation due to Patent Ductus Arteriosus Is Pronounced in Small-for-Gestational-Age Neonates. *Neonatology*. 2017; 111:126-132.
9. Chock VY, Rose LA, Mante JV, Pun R. Near-Infrared Spectroscopy for Detection of a Significant Patent Ductus Arteriosus. *Pediatr Res*. 2016;80(5): 675-680.
10. Lemmers PMA, Toet MC, van Bel F. Impact of Patent Ductus Arteriosus and Subsequent Therapy with Indomethacin on Cerebral Oxygenation in Preterm Infant. *Pediatrics*. 2008;121(1):142-147.
11. Schwarz CE, Preusche A, Wolf M, Poets CF, Franz AR. Prospective observational study on assessing the hemodynamic relevance of patent ductus arteriosus with frequency domain near-infrared spectroscopy. *BMC Pediatr*. 2018;18(1):66.
12. Noori S, Patel D, Friedlich P, Siassi B, Seri I, Ramanathan R. Effects of Low Oxygen Saturation Limits on The Ductus Arteriosus in Extremely Low Birth Weight Infants. *J Perinatol*. 2009;29(8):553-7.
13. Prescott S. Near Infrared Spectroscopy and Patent Ductus Arteriosus in The Preterm Neonate: A Systematic Review. *J Neonatal Nurs*. 2017;23(1):9-27.
14. Kissack CM, Garr R, Wardle SP, Weindling AM. Cerebral Fractional oxygen Extracton is Inversely Correlated with Oxygen Delivery in The Sick Newborn, Preterm Infant. *J Cereb. Blood Flow Metab*. 2005;25(5):545-553.
15. Howarth C, Banerjee J, Leung T, Eaton S, Morris JK, Aladangady N. Cerebral Oxygenation in Preterm Infants With Necrotizing Enterocolitis. *Pediatrics*. 2020;146(3):e20200337.
16. Dix L, van Bel F, Baerts W, Lemmers PMA. Comparing Near-Infrared Spectroscopy Devices and Their Sensors for Monitoring Regional Cerebral Oxygen Saturation in The Neonate. *Pediatr Res*. 2013; 74(5):557-563.
17. Poon WB, Tagamolila V. Cerebral perfusion and assessing hemodynamic significance for patent ductus arteriosus using near infrared red spectroscopy in very low birth weight infants. *J Matern Neonatal Med*. 2021;34(10):1645-1650.
18. Petrova A, Bhatt M, Mehta R. Regional tissue oxygenation in preterm born infants in association with echocardiographically significant patent ductus arteriosus. *J Perinatol*. 2011;31(7):460-4.
19. Gorman KM, Pinnamaneni RM, Franklin O, Foran A. Effects of ibuprofen on cerebral and somatic regional tissue oxygenation, using near-infrared spectroscopy in preterm infants <1500g with a patent ductus arteriosus. *J Clin Neonatol*. 2015;4(3):178-182.
20. Ledo A, Aguar M, Núñez-Ramiro A, Saénz P, Vento M. Abdominal Near-Infrared Spectroscopy Detects Low Mesenteric Perfusion Early in Preterm Infants with Hemodynamic Significant Ductus Arteriosus. *Neonatology*. 2017;112(3):238-45.
21. Dotinga BM, Mintzer JP, Moore JE, Hulscher JBF, Bos AF, Kooi EMW, et al. Maturation of Intestinal Oxygenation : A Review of Mechanisms and Clinical Implications for Preterm Neonates. *Front Pediatr*. 2020;8:354.
22. Gillam-Krakauer M, Cochran CM, Slaughter JC, Polavarapu S, Mcelroy SJ, Hernanz-Schulman M, et al. Correlation of abdominal rSO2 with superior mesenteric artery velocities in preterm infants. *J Perinatol*. 2013;33(8):609-12.
23. Guzoglu N, Sari FN, Ozdemir R, Oguz SS, Uras N, Altug N, et al. Renal and mesenteric tissue oxygenation in preterm infants treated with oral ibuprofen. *J Matern Neonatal Med*. 2014;27(2): 197-203.