

A Case Report of Neonatal Atrial Flutter with Poor Feeding and Tachypnea

Yazdan Ghandi^{1*}, Saeed Alinejad¹

1. Department of Pediatrics, School of Medicine, Amirkabir Hospital, Arak University of Medical Sciences, Arak, Iran

ABSTRACT

Background: Arrhythmias in neonates are not common and usually affect newborns with a normal heart or those that suffer from structural heart disease. A malignant type of arrhythmias is supraventricular tachycardia. Meanwhile, one uncommon type of supraventricular arrhythmias is atrial flutter (AFL), which is founded upon reentry mechanisms in the atrium. The AFL may result in heart failure or even death, but the majority of its cases have revealed favorable prognosis in the event of early prenatal diagnosis and immediate treatment.

Case report: A four-day term male newborn with a birth weight of 4,560 g born to a 43-year-old multiparous mother was delivered through cesarean section. The patient's admission to the hospital was on account of her poor feeding and tachypnea. The results of physical checkup exhibited tachycardia with 210 beats/min, and electrocardiogram (ECG) indicated a narrow QRS complex tachycardia with P-waves in the leads II and III that showed AFL. The adenosine injection revealed atrioventricular conduction 2.1. Therefore, oral propranolol therapy with a dosage of 3 mg/kg/day was prescribed for the patient. Given the recurrence of AFL, cardioversion was conducted with 0.25 joule/kg until the rhythm was restored to normal. Later, the normal sinus rhythm was observed on ECG. Fifteen days after birth, the patient was discharged with a perfect general state. The results of a 6-month follow-up did not show any AFL.

Conclusion: Despite its rare occurrence, AFL must be considered in the differential diagnosis of newborns with poor feeding with tachypnea and tachycardia.

Keywords: Arrhythmias, Atrial flutter, Neonate, Supraventricular tachycardia

Introduction

Neonatal arrhythmias occur in 1-5% of infants within the first days of life. Atrial flutter (AFL) represents a rare type of arrhythmia, which is based on the macro-reentry atrial tachycardia in neonates in early infancy (1). Tachycardia generally presents in newborns within the first 2 days of life. In some cases, it may be asymptomatic or even lead to severe heart failure in the need for urgent treatment.

One commonly-used method to diagnose AFL is an electrocardiogram (ECG), which is detected by the appearance of saw-like waves of flutter. Atrial rates may vary in the range of 280-450 bpm (2). Most cases could be converted to sinusoidal rhythm by the consumption of antiarrhythmic drugs or administration of atrial overdrive pacing

or electrical cardioversion. Sinus rhythm can be managed without taking any continuing arrhythmic drugs (3). The goal of this study was to present a case of idiopathic neonatal AFL through a review of literature and discussion of possible risk factors, features, prognosis, diagnosis, and therapeutic options.

Case report

A term male newborn 4 days old (with a gestational age of 39 weeks) with a birth weight of 4,560 g was admitted to the hospital. The infant was delivered through a cesarean section (C-section) and had a 43-year-old multiparous mother. The mother received insulin during pregnancy on the ground of her diabetes. The

* Corresponding author: Yazdan Ghandi, Department of Pediatrics, School of Medicine, Amirkabir Hospital, Arak University of Medical Sciences, Arak, Iran. Tel: +989378344116; Email: Drghandi1351@gmail.com

Please cite this paper as:

Ghandi Y, Alinejad S. A Case Report of Neonatal Atrial Flutter with Poor Feeding and Tachypnea. Iranian Journal of Neonatology. 2020 Mar; 11(1). DOI: [10.22038/ijn.2020.43455.1721](https://doi.org/10.22038/ijn.2020.43455.1721)

APGAR scores after 1 and 5 min were 9 and 10, respectively.

Any type of fetal arrhythmia was reported in prenatal history. The infant was discharged after birth. After 3 days, he was brought to the hospital due to poor feeding and tachypnea. Upon the first physical examination, the neonate was diagnosed with both tachycardia (220/bpm) and tachypnea (60/min) with a mean arterial pressure of 41 mmHg. The results of laboratory tests did not reveal any electrolyte disorder, such as potassium, sodium, and calcium. Accordingly, early infection, sepsis, and metabolic disorders were ruled out. Moreover, the results of blood culture and C-reaction Portion were negative. Laboratory tests, including electrolytes, and immunologic studies of the mother and infant were normal.

The Echo was also conducted, but the results did not reveal anything special other than small patent foramen ovale (PFO), mild tricuspid regurgitation (TR) (pressure gradient: 30 mmHg), and mild pulmonary regurgitation (PR) (pressure gradient: 40 mmHg) in the absence of any pulmonary branches stenosis (PPS), with ejection fraction (EF) of 55% and moderate pulmonary hypertension (PH). The results of other examinations and pulse oximetry were also normal. The newborn was transferred to a neonatal intensive care unit (NICU) after delivery. The tests of arterial blood gas exhibited pH 7.32, PaCO₂ 30, PaO₂ 70, HCO₃ 22, and base excess -4.9.

The ECG showed a narrow QRS complex, with P-wave appearing negative in the leads II, III, and aVF (Figure 1). Since ECG demonstrated supraventricular tachycardia (SVT), adenosine

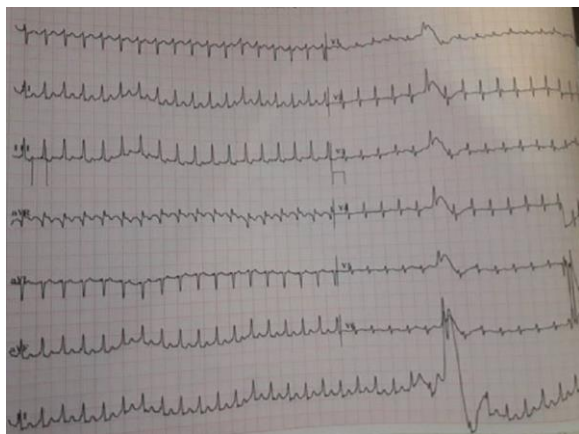


Figure 1. Narrow complex tachycardia, normal QRS complex, and P-waves with a ventricular rate of 210 beats/min; retrograde P-waves depicted in ST segment in leads of II, III, and aVF suggestive of atrial flutter with 2:1 atrioventricular conduction; detection of ventricular rate of 200-210 beats/min on 12-lead electrocardiogram

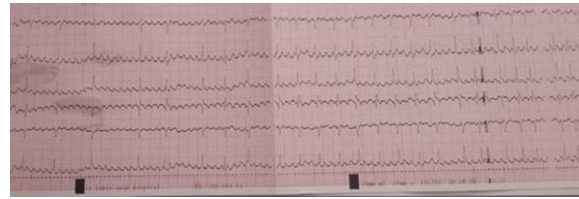


Figure 2. Atrial flutter with variable atrioventricular conduction after adenosine injection; obvious saw-tooth flutter pattern waves in leads

with a dosage of 0.3mg/kg/IV blues was administered. The ECG showed atrioventricular conduction AFL 2:1 (ventricular rate: 210/bpm, atrial rate: 485/bpm) (Figure 2). The oral propranolol therapy was started for the patient with a dosage of 1.0 to 3.0 mg/kg/d, three to four times a day. After 3 days, given the continuation of AFL and instability of hemodynamic, cardioversion was conducted with 0.25 j/kg after administering sedatives. The sinus rhythm became normal after conversion. The propranolol therapy was stopped after synchronized direct current (DC) cardioversion. In the absence of SVT recurrence, the newborn was discharged 15 days after birth with the administration of propranolol therapy.

In a 1-month follow-up, no AFL was detected, and corrected QT (QTc) was ruled out. Furthermore, the symptoms of the accessory pathway, including short PR interval, delta wave, and ECG, were all normal. The evaluation of Echocardiography did not show anything special other than small PFO, mild PR (pressure gradient: 40 mmHg), and mild TR (pressure gradient: 30) in the absence of PPS, with moderate PH and EF of 55%. Moreover, the results of other examinations and pulse oximetry were normal. The newborn was transferred to the NICU after delivery. The tests of blood gas at the time of admission showed pH 7.32, PaCO₂ 30, PaO₂ 70, HCO₃ 22, and base excess -4.9.

The ECG showed a narrow QRS complex, which appeared in the leads II, III, and aVF, and P-wave was negative (Figure 1). Since ECG demonstrated SVT, we administered adenosine with a dosage of 0.3mg/kg/ IV blues. The ECG exhibited atrioventricular conduction AFL 2:1 (ventricular rate: 210/bpm, atrial rate: 485/bpm) (Figure 2). Oral propranolol therapy started with a dosage of 1.0 to 3.0 mg/kg/d four times a day. Given the persistence of AFL and instability of hemodynamic after 3 days, cardioversion was conducted with 0.25 j/kg after administering sedatives.

The sinus rhythm became normal after conversion. The propranolol therapy was halted

after synchronized DC. In the absence of SVT recurrence, the infant was discharged 15 days after birth with the administration of propranolol therapy. The results of the 1-month follow-up did not show any AFL, and QTc was ruled out. Moreover, the symptoms of the accessory pathway, including the delta wave, ECG, and short PR interval, were normal.

Discussion

The AFL arrhythmia accounts for approximately 3% of cardiac arrhythmias in infants (4). The neonatal AFL is mostly asymptomatic and might be life-threatening in rare cases. The prognosis of this disease depends on the early detection and management of conditions in some grave cases. The AFL in infants often occurs in the first 7 days after birth. It is equally distributed between genders. Neonatal arrhythmias could be the extension of pre-birth diagnosed arrhythmia or detected accidentally after birth via the assessment of other nonspecific conditions, such as feeding difficulties, irritability, or even heart failure.

There is no consensus on the etiology of AFL, but it is generally believed that re-entry is caused by myocardium immaturity and high pressure in the right atrium during the perinatal period (5). Other major etiologies include a history of intra-atrial surgery, dilated atria, ischemic heart disease, and valvular disease, as well as acute infection, idiopathic conditions, and myocarditis in infants (6).

Newborns with AFL who are born to diabetic mothers are more likely to be macrosomic in comparison with the general population (6). However, neither gestational diabetes nor macrosomia appeared in our cases. The main factors in the clinical course include the emergence of signs, ventricle response to AFL, and duration of AFL.

The use of cocaine and/or opium by the mother has been shown to be linked to isolated AFL (7). It is believed that maternal lithium ingestion is associated with fetal AFL. Thus, it is recommended to conduct ECG for all newborns born to mothers treated with lithium during pregnancy (8). Other predisposing factors of AFL in infants are cardiac surgery and malposition of an umbilical artery catheter (9).

The AFL is associated with a regular rapid atrial tachycardia with wave patterns that resemble a sawtooth and are particularly evident in the leads of II, III, and aVF. Flutter waves with an atrial rate of up to 600 beats/min are typically

associated with 2:1 AV conduction in infants. There are two types of AFL. Type I (i.e., prevalent and typical) AFL is characterized with sawtooth flutter waves, along with an inverted P-wave axis in the inferior frontal leads (i.e., II, III, aVF, V1, V2).

Type II or atypical and uncommon type is characterized by similar arrhythmia and less obvious sawtooth appearance with a straight P-wave axis in the frontal lead. In the typical AFL, a predictable and critical region of slow conduction is used by re-entry as tachycardia propagates in a counterclockwise manner from the atrial free wall via the isthmus of the myocardium, which is located between tricuspid annular and inferior vena cava toward the septum. In the atypical AFL, re-entry has a clockwise flow.

The AFL management strategies typically involve terminating tachycardia, consolidating sinus rhythm, and hampering recurrences. The DC cardioversion is the preferred treatment in acute cases when there is a severe hemodynamic compromise. However, it could also be ended with temporary transesophageal or transvenous pacing. In cases that are hemodynamically stable, acute therapy requires a more accurate approach. In general, beta-blockers and calcium channel blockers are more reliable than digoxin to induce control ventricular response. The refractory AFL is assumed to be a serious complication in newborns, but the recurrence of AFL is uncommon, and long-run medication therapy is required in rare cases.

Under these conditions, drugs that have shown the highest effectiveness in impeding recurrences include class I (i.e., IA and IC) and class III medications. However, it seems that many patients are refractory to all types of drugs. Thus, different antiarrhythmic medications, such as quinidine, digoxin, flecainide, procainamide, propranolol, sotalol, and amiodarone, have been utilized separately or in combination, and various success rates have been reported.

Digoxin is recommended for the treatment of neonatal AFL. In patients receiving digoxin, it is advised to avoid electrical cardioversion, unless there is a life-threatening condition. It is because the combination is associated with malignant ventricular arrhythmias. However, due to the higher risk of ventricular tachycardia and cardioversion after digitalization, digoxin was not the preferred choice in our case (2, 3).

It has been shown that external electrical cardioversion and propafenone therapy are effective for refractory neonatal AFL (10). Thus, in some cases, nonmedical treatments are required.

In such cases, there are several choices, such as catheter ablation, anti-tachycardia pacing, surgical revision, or a combination of them. When a patient is not hemodynamically stable, cardioversion is the preferred treatment. However, when the patient is clinically stable, antiarrhythmic drugs are recommended (2). Our case displayed the clinical symptoms of mild heart failure. Nevertheless, we started medical treatment that continued for 3 days.

After 36 weeks of pregnancy, postnatal medications, such as synchronized DC cardioversion or transesophageal overdrive pacing, could be used as therapeutic methods (11). In this context, the preferred treatment is synchronized cardioversion at 0.25-0.5 J/kg. Atrial overdrive pacing is also another alternative when the atrial rate is slow, though its administration in newborns is challenging due to the exceptionally rapid rate. The DC cardioversion is often effective, with a success rate higher than 85-90%, but transesophageal pacing has a lower success rate (3, 11, 12).

After DC cardioversion, in the absence of any evidence of other congenital or arrhythmias heart diseases, there is no need to perform antiarrhythmic therapy or follow-up for infants. In the absence of other types of arrhythmias, infants with AFL usually have an excellent prognosis once sinus rhythm is restored, with a diminished risk of recurrence. Also, chronic antiarrhythmic treatment is probably unnecessary.

Finally, to improve recognition, a comparison has been drawn between the results of our patients and two recent studies. Roumiantsev S et al. described an infant born through spontaneous vaginal delivery after 36 and 37 weeks of pregnancy. The prenatal history of the mother was important for insulin dependency, chorioamnionitis, and premature rupture of membranes more than 24 h. The newborn was large for gestational age (99%), and the symptoms of mild respiratory distress syndrome were evident. The AFL occurred 40 h after birth. The medical therapy started with esmolol hydrochloride followed by fentanyl and cardioversion, which recovered normal sinus rhythm (13). By analogy, the neonate in our study was not born to a diabetic mother, but he was heavier and discharged from the hospital. Furthermore, he was admitted for tachypnea and eating disorders. The newborn in our study also displayed a better therapeutic response.

Yilmaz-Semerçi S et al. reported neonatal AFL in three cases. All of the patients had a good prognosis without any recurrence following the

treatment response. The risk factors of patients in that study were different from those of our patient. In that study, all three patients were delivered through C-section. They did not have diabetic mothers or infections and weighed less than our patient. These may explain the undesirable response to first-line treatments in these patients (14). In our case, there were obvious clinical manifestations. The AFL is frequently associated with palpitation and low cardiac output. However, the patient in our study was admitted with tachypnea and poor feeding indicating that the admitted patient was suspected of pneumonia or early sepsis.

Conclusion

The AFL in neonates may be resistant to first-line treatments, such as beta-blockers (e.g., propranolol). Thus, secondary therapies, such as sotalol, amiodarone, and cardioversion, if necessary, might be effective for the treatment of perinatal tachyarrhythmia. In the absence of other types of arrhythmias or congenital heart disease after cardioversion, it is not necessary to perform antiarrhythmic therapy for these newborns. It is of paramount importance to follow up these patients after discharge, and the newborn should be brought to all follow-up appointments. Newborns with AFL often have a promising prognosis once the sinus rhythm has been restored with a decreased risk of recurrence. Although AFL is rare, it should be considered in the differential diagnosis of newborns with poor feeding and high heart rate.

Acknowledgments

The authors would like to express their gratitude to all patients' families for their contribution to this study.

Conflicts of interests

The authors declare that there is no conflict of interest.

References

1. Kundak AA, Dilli D, Karagol B, Karadag N, Zenciroglu A, Okumus N, et al. Non benign neonatal arrhythmias observed in a tertiary neonatal intensive care unit. *Indian J Pediatr.* 2013; 80(7):555-9.
2. Tunaoglu FS, Yildirim A, Akca A. Atrial flutter neden olan hamak mitral kapak: Üç aylık bebek olgu. *Türk Pediatri Arşivi.* 2013; 48(3):244-7.
3. Özdemir R, Altug N, Dizdai E, Yurttutan S, Öncel MY, Erdeve Ö, et al. Prematüre bir yenidoğanda kardiyoversiyon ile tedavi edilen atriyal flutter

- olgusu. Türkiye Çocuk Hastalıkları Dergisi. 2013; 7(1):47-9.
4. Southall D, Johnson A, Shinebourne E, Johnston P, Vulliamy D. Frequency and outcome of disorders of cardiac rhythm and conduction in a population of newborn infants. *Pediatrics*. 1981; 68(1):58-66.
 5. Wanamaker B, Cascino T, McLaughlin V, Oral H, Latchamsetty R, Siontis KC. Atrial Arrhythmias in pulmonary hypertension: pathogenesis, prognosis and management. *Arrhythm Electrophysiol Rev*. 2018; 7(1):43-8.
 6. Pike JJ, Krishnan A, Kaltman J, Donofrio MT. Fetal and neonatal atrial arrhythmias: an association with maternal diabetes and neonatal macrosomia. *Prenat Diagn*. 2013; 33(12):1152-7.
 7. Gad A, Morelli P, Decristofaro J. Perinatal isolated atrial flutter associated with maternal cocaine and opiate use in a late preterm infant. *J Matern Fetal Neonatal Med*. 2010; 23(9):1062-5.
 8. Wilson N, Forfar JD, Godman MJ. Atrial flutter in the newborn resulting from maternal lithium ingestion. *Arch Dis Child*. 1983; 58(7):538-9.
 9. Texter KM, Kertesz NJ, Friedman RA, Fenrich AL Jr. Atrial flutter in infants. *J Am Coll Cardiol*. 2006; 48(5):1040-6.
 10. Gulletta S, Rovelli R, Fiori R, Bella PD. Multiple external electrical cardioversions for refractory neonatal atrial flutter. *Pediatr Cardiol*. 2012; 33(2):354-6.
 11. Lulic Jurjevic R, Podnar T, Vesel S. Diagnosis, clinical features, management, and post-natal follow-up of fetal tachycardias. *Cardiol Young*. 2009; 19(5):486-93.
 12. Ceresnak SR, Starc TJ, Hordof AJ, Pass RH, Bonney WJ, Liberman L. Elevated impedance during cardioversion in neonates with atrial flutter. *Pediatr Cardiol*. 2009; 30(4):436-40.
 13. Roumiantsev S, Settle MD. Atrial flutter in the neonate: a case study. *Neonatal Netw*. 2017; 36(5):313-7.
 14. Yilmaz-Semerçi S, Bornaun H, Kurnaz D, Cebeci B, Babayigit A, Buyukkale G, et al. Neonatal atrial flutter: three cases and review of the literature. *Turk J Pediatr*. 2018; 60(3):306-9.