

Varicella Zoster Infection in Infancy (A Very Rare Case Report)

Mohammad Razmyar¹, Abdolkarim Hamed²*

1. Dermatology Department Hazrat Rasoul Hospital Ferdows, Birjand University of Medical Science, Birjand, Iran

2. Infection Control and Hand Hygiene Research Center, Faculty of Medicine, Mashhad University of Medical Science, Mashhad, Iran

ABSTRACT

Background: Herpes zoster occurs due to reactivation of varicella zoster-virus (VZV) that is latent in dorsal root ganglion cells after primary varicella infection. It can occur in any age but is very rare during infancy. Acquisition of this virus in utero or early after birth may result in infantile herpes zoster.

Case report: Here, it is aimed to report an infant with herpes zoster whom his mother had developed varicella two years before pregnancy.

Conclusion: Despite the rarity of shingles in infants after birth, any infant who has a vesicular lesion in a particular neurological dermatome should be aware of the disease.

Keywords: Infant, Herpes zoster, Vesicular rash

Introduction

VZV that is usually transmitted by airborne droplets and contact, results in varicella infection and then the virus be transferred to dorsal root ganglion cells from mucocutaneous lesions, where stays there permanently. Reactivation of this hidden VZV, results in herpes zoster or shingles that can happen at any age (1). However, this occurrence is rare during childhood and very rarer during infancy (2) and usually occurs in an infant whom her/his mother has developed varicella during pregnancy (3). Here, it is going to be reported a 75-days-old male infant with herpes zoster and unknown origin of obtaining VZV.

Case report

A healthy 75 days old male infant was referred to hospital with 3 days history of irritability and cutaneous rash. His temperature was 37.2°C. His weight at the time of birth was 2900 g (at presentation was 5500 g), and his head circumference was 37 cm. On physical examination, numerous grouped vesiculobullous eruptions on erythematous base in linear

distribution on the left side of his chest along T5-6 dermatomes were seen (Panel A). The rest of the cutaneous examinations were unremarkable.

Varicella had involved his mother 2 years before pregnancy also she has had close contact with the person involving by varicella during the first trimester of her pregnancy and has not had complicated pregnancy. Tzank smear revealed multinucleated giant cells (Panel B). IgM and IgG anti-VZV antibodies were high. For him, herpes zoster infection was diagnosed. Finally, after 6 days he discharged home while most of the lesions were crusted.

The best way to diagnose herpes virus groups is Tzank smear test, which is determined by a pathologist.

Discussion

VZV is an alpha human herpesvirus that results in varicella and herpes zoster. Varicella is an extremely contagious primary infection while herpes zoster occurs due to reactivation of latent VZV in dorsal root ganglion cells. This

*Corresponding author: Abdolkarim Hamed, Infection Control and Hand Hygiene Research Center, Faculty of Medicine, Mashhad University of Medical Science, Mashhad Iran. Tel: +989151145827; Email: Hamedia@mums.ac.ir

Please cite this paper as:

Razmyar M, Hamed A. Varicella Zoster Infection in Infancy (A Very Rare Case Report). Iranian Journal of Neonatology. 2020 Sep; 11(3). DOI: [10.22038/IJN.2020.49154.1855](https://doi.org/10.22038/IJN.2020.49154.1855)

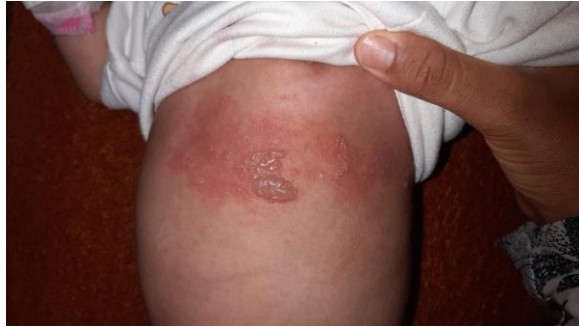

Figure 1. Vesiculobullous rash on T5-6 dermatomes

reactivation that can happen in any age may be spontaneous or as a consequence of following reasons: fever, stress, local trauma, radiation and immunosuppression (1). If a pregnant woman develops varicella during her third trimester, the newborn may suffer neonatal varicella or infantile herpes zoster (4); the latter may occur without developing varicella (1). Also, herpes zoster during infancy may be due to acquiring VZV in utero or early infancy (2). Interestingly, our patient's mother had developed varicella two years before pregnancy and our patient has not had varicella before and had no signs of varicella embryopathy. The occurrence of herpes zoster is rare during childhood and very rarer during infancy (2). There are some reports of herpes zoster during infancy in which mother had varicella during pregnancy or has had close contact with a person with varicella (3-8), but in our case, she didn't have. Brar et al reported the youngest infant with herpes zoster that was 16 days old (7). Weller postulated that the immature immune system is responsible for a short interval between primary infection and reactivation of VZV (9) and this immaturity results in inadequate antibodies production and subsequent herpes zoster occurrence (7). Differential diagnosis for vesiculobullous eruptions in infancy includes: bullous reaction to insect bites, impetigo, herpes simplex virus infection and pityriasis lichenoides et varioliformis acuta (1). Since our patient has not developed varicella before and his mother had had varicella 2 years before pregnancy, it is unclear how the patient has gotten such a virus. The cause of it might be maternal, congenital or postnatal.

Ethics: Conscious consent was obtained from

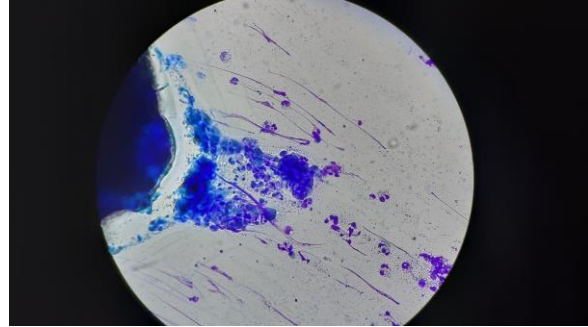


Figure 2. multinucleated giant cells on Tzanck smear

the parents with explanations about the publication of the patient's photo and information.

Conclusion

Despite the rarity of shingles in infants after birth, any infant who has a vesicular lesion in a particular neurological dermatome should be aware of the disease.

Acknowledgments

None.

Conflicts of interests

None.

References

1. Downing C, Mendoza N, Sra K, Tyring SK. Human herpesviruses. In: Bologna JL, Jorizzo JL, Schaffer JV, editors. *Dermatology*. 4th ed. Philadelphia: Elsevier; 2018. P. 1400-24.
2. Laude TA, Rajkumar S. Herpes zoster in a 4-month-old infant. *Arch Dermatol*. 1980; 116(2):160.
3. Gupta LK, Khare AK, Mittal A, Kuldeep CM. Herpes zoster in infancy. *Indian Dermatol Online J*. 2013; 4(3):252-4.
4. Brunell PA. Varicella-zoster infections in pregnancy. *JAMA*. 1967; 199(5):315-7.
5. Handa SA. Herpes zoster in a 3-month-old infant. *Pediatr Dermatol*. 1997; 14(4):333.
6. Jain A, Singal A, Baruah MC. Herpes zoster in a 9-month-old infant. *Indian J Dermatol Venereol Leprol*. 1999; 65(6):294-5.
7. Brar BK, Pall A, Gupta RR. Herpes zoster neonatorum. *J Dermatol*. 2003; 30(4):346-7.
8. Helander I, Arstila P, Terho P. Herpes zoster in a 6-month-old infant. *Acta Derm Venereol*. 1983; 63(2):180-1.
9. Weller TH. Varicella and herpes zoster: (First of Two Parts). *N Engl J Med*. 1983; 309(22):1362-8.