

Association of Dandy-Walker Malformation and Neurocutaneous Melanosis in a Newborn: A Case Report

Azamolmolouk Elsagh¹, Ali Reza Jashni Motlagh^{2*}

1. Faculty of Nursing, Alborz University of Medical Sciences, Karaj, Iran

2. Kamali Clinical Research and Developmental Unit, Alborz University of Medical Sciences, Karaj, Iran

ABSTRACT

Background: This case report presents a very rare Dandy-Walker malformation (DWM) in association with a sporadic condition characterized by congenital melanocytic nevi and melanocytic thickening of the leptomeninges called Neurocutaneous melanosis (NCM). The DWM is a rare congenital disorder characterized by enlarged posterior fossa and a cystic enlargement of the fourth ventricle with cerebellar vermis dysgenesis. This association is a very rare complex, and this is another rare case to be reported in the literature.

Case report: A full-term newborn was presented with tachypnea at birth whose hydrocephalous was reported prenatally. The magnetic resonance imaging and cerebrospinal fluid immunohistochemistry confirmed leptomeningeal melanosis. After documenting findings by skin biopsy, we decided to report this case. Diagnosis and treatment for such disease entity are discussed in this report.

Conclusion: Even without malignant transformation, the prognosis is poor after symptomatic progression of the NCM resulting from either mass effect in the central nervous system or hydrocephalus. We reported this case in order to increase the knowledge of pediatric physicians to diagnose this combined situation.

Keywords: Dandy-walker malformation, Neurocutaneous melanosis, Newborn

Introduction

Dandy-Walker Malformation (DWM) is a rare congenital disorder that is characterized by the triad of the enlarged posterior fossa, cystic enlargement of the fourth ventricle, and cerebellar vermis dysgenesis (1-4). Clinical features include occipital bossing, progressive head enlargement, bulging of anterior fontanelle, papilledema, ataxia, gait disturbances, nystagmus, and intellectual compromise (Menkes, Textbook of Child Neurology, 5th ed, pp294-5). Hydrocephalus is shown in approximately 70-90% of patients which usually develops postnatally (5). The effect of DWM is highly variable on intellectual development and ranges from normal or nearly normal development to profound disability or even early death (6-8). Motor deficits, such as delayed motor development, hypotonia, and ataxia are the effects of DWM. These patients have mental retardation and some have hydrocephalus (9).

Several studies have reported Dandy-Walker malformation to be associated with central nervous system abnormalities (10). One of this anomalies is Neurocutaneous melanosis (NCM) that is also a rare congenital and non-inherited dysplasia characterized by large or multiple melanocytic nevi leading to the proliferation of melanin-producing cells in the skin and leptomeninges (2, 11-13). It is believed that abnormal neural crest cell differentiation and migration which is usually governed by specific genes (i.e., PAX3, ZIC2, WNT, SLUG, SOX10) results in the NCM (14).

There is no embryological explanation for the origin of this disorder. The diagnostic criteria, which were first described by Fox and later revised by Kadonaga and Frieden in 1991, include the combination of all of the following: A single giant congenital nevus (measuring at its greatest diameter ≥ 20 cm in adults or ≥ 9 cm on the head

* Corresponding author: Ali Reza Jashni Motlagh, Kamali Clinical Research and Developmental Unit, Alborz University of Medical Sciences, Karaj, Iran. Tel: +989123337622; Email: aj_motlagh@yahoo.com

Please cite this paper as:

Elsagh A, Jashni Motlagh AR. Association of Dandy-Walker Malformation and Neurocutaneous Melanosis in a Newborn: A Case Report. Iranian Journal of Neonatology. 2019 Sep; 10(3). DOI: [10.22038/ijn.2019.41396.1679](https://doi.org/10.22038/ijn.2019.41396.1679)

or ≥ 6 cm on the trunk in neonates and infants) or multiple (three or more) congenital nevi accompanied by meningeal melanosis or central nervous system melanoma (15).

Clinically, patients can experience seizures, hydrocephalus, developmental delays, psychiatric disorders, cranial nerve palsies, intracranial hemorrhage, and myelopathy (16). Seizures are the most common initial neurological manifestation (17). The association of NCM and DWM is even rarer. A better understanding of this disease will facilitate the development of new strategies (18). We report the clinical features, neuroimaging findings, and therapeutic management of a rare case of neurocutaneous melanosis associated with DWM.

Case report

A full-term male newborn, the first child of a family, was born in our hospital by cesarean delivery. He was born from non-consanguineous parents. There was no family history of a similar condition. He was presented with mild tachypnea, excessive crying, and increasing in size of head circumference. Moreover, he had hypertonia and was alert. His birth weight was 3400gr (50th-75th percentile) with the height of 51cm (50th percentile), and occipitofrontal circumference of 36.5cm (75th percentile). The Apgar scores were 8 and 9 at the 1st and 5th minutes of life,

respectively. His appearance was good in general while his blood pressure, other vital signs, and heart sounds were normal as well as other chest exams. No organomegaly was detected in the abdominal physical examination. He was diagnosed with a prenatal ultrasonographic diagnosis of hydrocephalus and he had wide fontanels on his physical examination. There were nine well defined, non-hairy, hyperpigmented nevi with regular borders seen all over his body (figures 1a, b). Three giant nevi were observed at the lower back. The nevi biopsy confirmed Neurocutaneous melanosis.

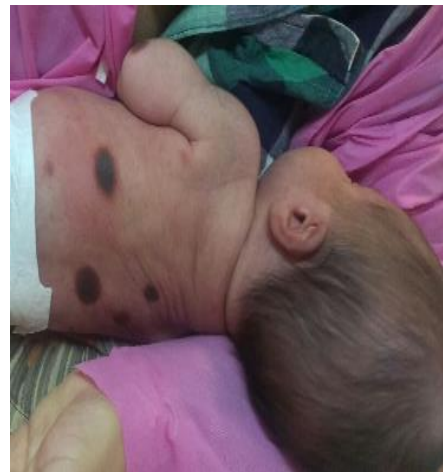

Figure 1. Nevus extending to the whole body

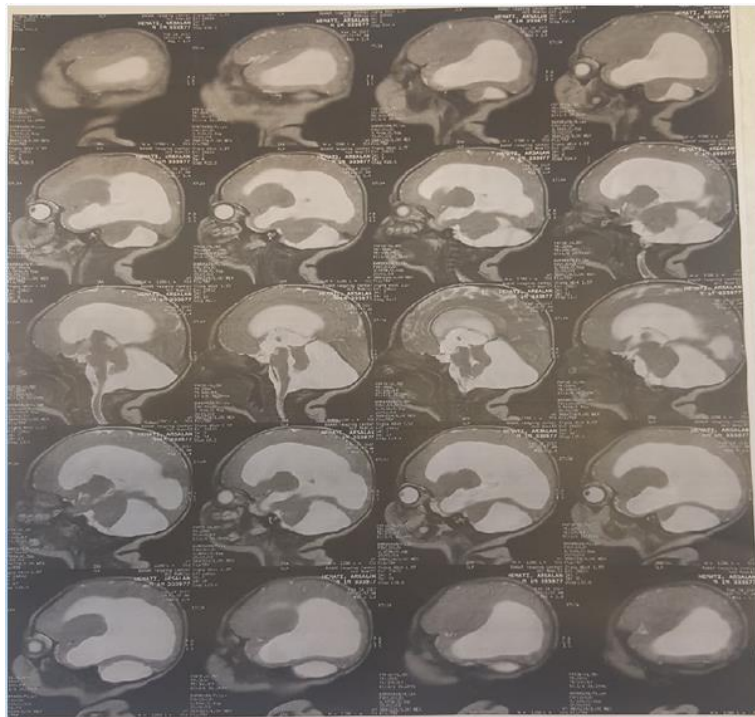

Figure 2. Computed tomography scan showing a large cystic lesion in posterior fossa and dilation in lateral and third ventricles

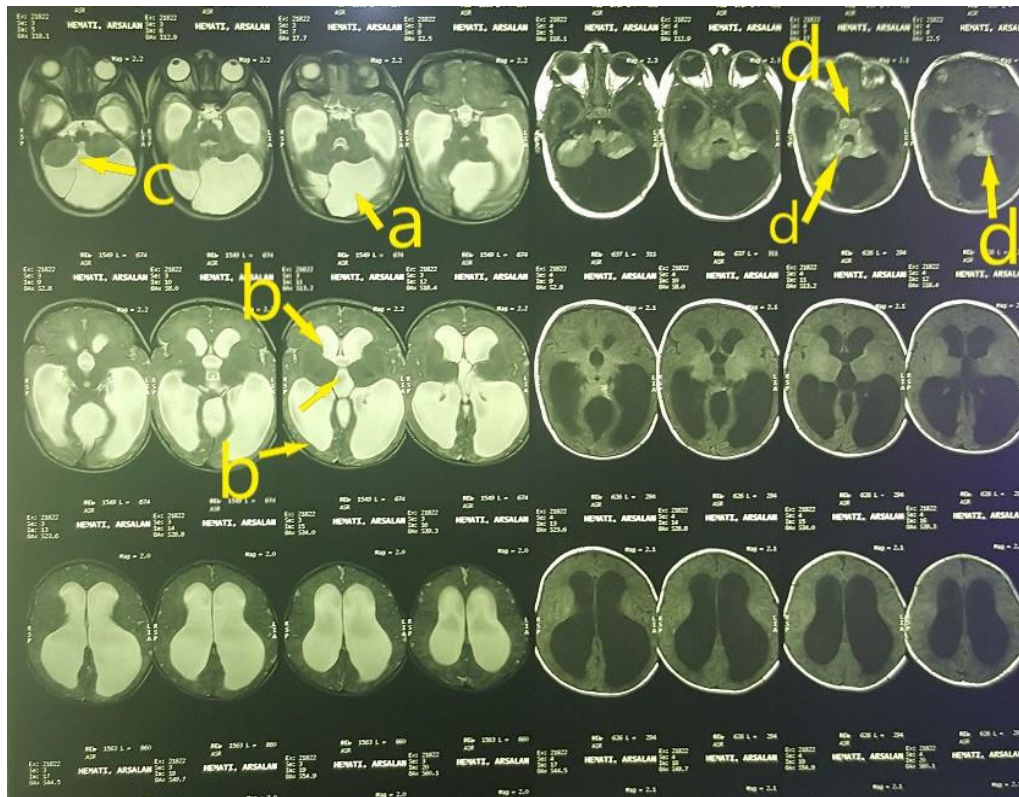


Figure 3. Magnetic resonance imaging revealing a large cystic lesion in the posterior fossa (a), lateral and 3rd ventricle dilatation (b), a hypoplastic cerebellar vermis (c), and marked signal changes of cerebellar hemispheres and the right side of pons (d)

His brain computed tomography (CT) scan at the second day of birth showed a large cystic lesion in the posterior fossa resulted in atrophy of both cerebellar hemispheres and dilation in lateral and third ventricles (Figure 2). His brain magnetic resonance imaging (MRI) revealed a large cystic lesion in posterior fossa, lateral and 3rd ventricle dilatation, a hypoplastic cerebellar vermis, marked signal changes of cerebellar hemispheres and right side of pons (Figure 3). The newborn referred to an equipped hospital for receiving supportive treatment and shunt placement. Afterward, the head circumference decreased slightly and no new neurological deficits were observed in this rare case.

Discussion

We reported a case of Dandy-Walker Malformation, a newly born presented with neurocutaneous Melanosis. The diagnostic criteria which were described by D'Argenio were the same as those by Kadonaga and Frieden which include large congenital melanocytic nevi that are defined as those ≥ 20 cm in adults, ≥ 9 cm on the head, or >6 cm on the trunk in neonates. "Multiple" is defined as more than three. These

specific diagnostic criteria allowed their distinction from CNS metastases of primary skin melanoma (19). Our case was defined as Multiple Neurocutaneous Melanosis. Giant congenital melanocytic nevus, usually at the Lumbosacral region, is observed in two-thirds of patients with NCM (2). In our patient, three giant nevi were seen in the Lumbosacral region.

Dandy-walker syndrome characterized by agenesis or hypoplasia of the cerebellar vermis, cystic dilatation of the fourth ventricle, and the enlargement of the posterior fossa (12, 20-24). According to the above criteria, our case had all of these features. The combination of NCM with DWM are very rare and fewer than 32 cases have been reported in the literature (20-22, 25).

Hydrocephalus also results from the associated DWM probably secondary to the induction failure of the opposing cerebral plates at or before the seventh weeks of gestation. The signs and symptoms of hydrocephalus appear early in our patient due to the observed pathologies of NCM and DWM.

Based on the result of a study by Mallikarjun K in 2010, the severity of DWM depends on the presence of other anomalies. Totally, two-thirds of

infants have associated central nervous system abnormalities (8), such as NCM which is also found in our study. Parisi MA showed that cutaneous congenital melanocytic nevi were usually recognized at birth. The confirmation of the diagnosis of NCM was made by histological findings, such as endoscopy or biopsy (26) which was done for our patient. The paramagnetic properties of melanin and the sensitivity of MRI led to the diagnosis of NCM as well as DWM.

In the same line, in a case report of Neurocutaneous Melanosis conducted by Bittencourt FV, it was revealed that the most common neurological symptoms and signs were related to hydrocephalus, such as seizures, cranial nerve dysfunction, and signs of the spinal cord and root involvement (27). These results are in line with the findings observed in our case. Hydrocephalus also results from the association of DWM and NCM; however, the signs and symptoms of hydrocephalus may appear later in life (28). Nonetheless, it was diagnosed prenatally in our case. Furthermore, in a study performed by Steiner, the poor prognosis was observed for the association of NCM and DWM. The patients usually die before the age of 4 with the malignancy transformation and neurological complications which are reported to occur in 51.5% of the patients (13).

The characteristics of neuroimaging studies, such as CT or MRI for our case of neurocutaneous melanosis with Dandy-Walker malformation are not different from those in previous cases. The interesting feature of our case included no leptomeningeal infiltration of the melanosis or melanoma. Moreover, in a literature review, Mena-Cedillos CA reported that despite the surgical treatment, chemotherapy, and cortisol therapy, more than half of all patients will die within 3 years after the manifestation of the neurological symptoms (29), and we should follow our patient till that time.

Conclusion

This rare condition which was seen in our patient should be followed up in the first years of life. In addition, it is necessary to take good care of them before discovering new treatment modalities for this disorder.

Acknowledgments

The authors would like to thank Dr. Mohsen Khodarahmi (MD) who performed brain MRI and CT scan. They also like to express their gratitude to the respected dermatologist, Dr. Marjan Saeedi,

who contributed greatly to the diagnosis. In addition, they thank the neonate and the infant's parents who allowed us to report this case. They would also like to thank their colleagues and staff members and all those who contributed to conducting this study.

Conflicts of interests

The authors of this study declared no conflicts of interest.

References

1. Bokhari I, Rehman L, Hassan S, Hashim MS. Dandy-Walker malformation: a clinical and surgical outcome analysis. *J Coll Physicians Surg Pak.* 2015; 25(6):431-3.
2. Swar MO, Mahgoub SM, Yassin RO, Osman AM. Dandy-Walker malformation and neurocutaneous melanosis in a three-month-old infant. *Sudanese J Paediatr.* 2013; 13(2):61.
3. Rohanachandra YM, Dahanayake DM, Wijetunge S. Dandy-Walker malformation presenting with psychological manifestations. *Case Rep Psychiatry.* 2016; 2016:9104306.
4. Cho IY, Hwang SK, Kim SH. Dandy-walker malformation associated with neurocutaneous melanosis. *J Korean Neurosurg Soc.* 2011; 50(5):475.
5. Abdulabbas AM, Zghair MA, Al-Khayat RH. Disorders of the cerebellum in children, MRI-clinical correlation. *Iraqi Acad Sci J.* 2016; 15(1):13-8.
6. Al-Turkistani HK. Dandy-Walker syndrome. *J Taibah Univ Med Sci.* 2014; 9(3):209-12.
7. Vundinti BR, Kerketta L, Korgaonkar S, Ghosh K. Dandy-Walker malformations in a case of partial trisomy 9p (p12. 1→ pter) due to maternal translocation t(9; 12)(p12. 1; p13. 3). *Indian J Hum Genet.* 2007; 13(1):33.
8. Mallikarjun K, Vatsala V, Bhayya DP. Dandy-Walker syndrome-a rare case report. *J Adv Oral Res.* 2010; 1(1):67-70.
9. Scattolin MA, Lin J, Peruchi MM, Rocha AJ, Masruha MR, Vilanova LC. Neurocutaneous melanosis: follow-up and literature review. *J Neuroradiol.* 2011; 38(5):313-8.
10. Jalali A, Aldinger KA, Chary A, Mclone DG, Bowman RM, Le LC, et al. Linkage to chromosome 2q36. 1 in autosomal dominant Dandy-Walker malformation with occipital cephalocele and evidence for genetic heterogeneity. *Hum Genet.* 2008; 123(3):237-45.
11. Zhang W, Simos P, Ishibashi H. 2.7 Neurocutaneous melanosis. *Neurocutaneous Disord Clin Diagn Ther Appr.* 2016; 14:142.
12. Shooshtari S, Stoesz BM, Rad P, Khoeiniha S. Epidemiology of cerebellar disorders. Development of the cerebellum from molecular aspects to diseases. Cham: Springer; 2017. P. 423-63.
13. Steiner JE, McCoy GN, Hess CP, Dobyns WB, Metry DW, Drolet BA, et al. Structural malformations of the brain, eye, and pituitary gland in PHACE syndrome. *Am J Med Genet Part A.* 2018; 176(1):48-55.

14. Samat HB, Flores-Samat L. Embryology of the neural crest: its inductive role in the neurocutaneous syndrome. *J Child Neurol*. 2005; 20(8):637-43.
15. Kadonaga JN, Frieden IJ. Neurocutaneous melanosis: definition and review of the literature. *J Am Acad Dermatol*. 1991; 24(5):747-55.
16. Ramaswamy V, Delaney H, Haque S, Marghoob A, Khakoo Y. Spectrum of central nervous system abnormalities in neurocutaneous melanocytosis. *Dev Med Child Neurol*. 2012; 54(6):563-8.
17. Moreira BL, Grunewald T, Côrtes AA, Marussi VH, Amaral LL. Neurocutaneous melanosis. *Radiol Brasil*. 2016; 49(6):412-3. Moreira, B. L., Grunewald, T., Côrtes, A. A., Marussi, V. H., & do Amaral, L. L. (2016). Neurocutaneous melanosis. *Radiologia brasileira*, 49(6), 412–413. doi:10.1590/0100-3984.2015.0128
18. Linares AR, Moya AS, Felix V, Campos Y. Congenital melanocytic nevus syndrome: a case series. *Actas Dermo Sifiliográficas*. 2017; 108(9):e57-62. Linares, A. R., Moya, A. *Actas Dermo-Sifiliográficas* (English Edition)108
19. D'Argenio A, David P, Engohan C, Hennequin Y, Balériaux D, Jissendi P. Neurocutaneous melanosis in a newborn with giant congenital melanocytic nevus. *J Neuroradiol*. 2007; 34(4):272-5.
20. Berker M, Oruckaptan HH, Oge HK, Benli K. Neurocutaneous melanosis associated with Dandy-Walker malformation. *Pediatr Neurosurg*. 2000; 33(5):270-3.
21. Jakchairongruang K, Khakoo Y, Beckwith M, Barkovich AJ. New insights into neurocutaneous melanosis. *Pediatr Radiol*. 2018; 48(12):1786-96.
22. Chen YA, Woodley-Cook J, Sgro M, Bharatha A. Sonographic and magnetic resonance imaging findings of neurocutaneous melanosis. *Radiol Case Rep*. 2016; 11(1):29-32.
23. Bhatt TA, Dagherri A, Shakweer WA. Neurocutaneous melanosis with pulmonary metastasis: looking beyond the skin. *J Dermat Cosmetol*. 2019; 3(2):42-4.
24. Sharouf F, Zaben M, Lammie A, Leach P, Bhatti MI. Neurocutaneous melanosis presenting with hydrocephalus and malignant transformation: case-based update. *Child Nervous Syst*. 2018; 34(8): 1471-7.
25. Sung KS, Song YJ. Neurocutaneous melanosis in association with Dandy-Walker complex with extensive intracerebral and spinal cord involvement. *J Korean Neurosurg Soc*. 2014; 56(1):61.
26. Parisia MA, Dobyns WB. Human malformations of the midbrain and hindbrain: review and proposed classification scheme. *Mol Genet Metab*. 2003; 80(1-2):36-53.
27. Bittencourt FV, Marghoob AA, Kopf AW, Koenig KL, Bart RS. Large congenital melanocytic nevi and the risk for development of malignant melanoma and neurocutaneous melanocytosis. *Pediatrics*. 2000; 106(4):736-41.
28. Chang TW, Hsieh PC, Liu ZH, Tu PH. Adult-onset neurocutaneous melanosis with Dandy-Walker malformation. *Formosan J Surg*. 2018; 51(3):118.
29. Mena-Cedillos CA, Valencia-Herrera AM, Arroyo-Pineda AI, Salgado-Jiménez MA, Espinoza-Montero R, Martínez-Avalos AB, et al. Neurocutaneous melanosis in association with the Dandy-Walker complex, complicated by melanoma: report of a case and literature review. *Pediatr Dermatol*. 2002; 19(3):237-42.