

Association of vertebral, anal, cardiac, tracheoesophageal, renal and limb anomalies with auricle atresia; a case report

Sedigh Jahanshahifard^{1*}, Hossein Saadat², Mousa Ahmadpour-Kacho³
Sohail Osia⁴, Yadolla Zahedpasha⁵

1-2-3-4-5-Non-communicable Pediatric disease research center, AmirKola Children Hospital, Babol University of Medical Sciences, Babol, Iran *(Corresponding author: m.jahanshahifard@gmail.com Tel: +98-913-309-3982)

Abstract

Association of vertebral, anal, cardiac, tracheoesophageal, renal and limb anomalies (VACTERL) is rare anomaly with an incidence of 1.6 per 10000 births. This condition is a combination of anomalies recognized as a hereditary entity with poor prognosis. Herein, we report VACTERL association presenting with auricle atresia. A male neonate with a birth weight of 2690 grams, head circumference 34 cm, full term, delivered via Cesarean section (C/S) to a 23 year-old mother G2P2L2A0 is presented. The patient was born with APGAR score 7/10 in 1 and 5 minutes. He had multiple congenital anomalies including sacral agenesis, anal atresia, and heart murmur compatible with the diagnosis of patent ductus arteriosus, TEF, multicystic kidney disease, atresia of both auricles and external ear canal. He had characteristics of the VACTERL association, In addition to this combination of malformation, we found him to have ear anomalies.

Keywords:

Auricle atresia, Neonate, Vacterl

Introduction

An association is defined as two or more anomalies that are not pathologically related and occur together more frequently than expected by chance. In general, the etiology of an association is not defined (1-3).

VACTERL is an association; this acronym refers to anomalies of the vertebrae (V), atresia in the gastrointestinal tract or anus (A), cardiac anomaly (C), tracheoesophageal defect (TE), renal and distal urinary tract anomalies (R) and limb defect (L) (4, 5).

In a review done by Kecklor, during a 20-year period neonates born with esophageal atresia were described as were the type and incidence of associated lesions (Table 1). Although prenatal diagnosis of VACTERL association is not always possible, ultrasonography and magnetic resonance imaging can visualize some of the characteristic findings of this condition (6) David et al in

1996 reported a case with a combined defect of blastogenesis consisting of Nager acrofacial dysostosis, MURCUS association (Müllerian duct aplasia, renal aplasia, cervicothoracic somite dysostosis with Klippel-Feil anomaly), VACTERL and left pulmonary agenesis. These disorders occurred during the third or the fourth week of embryonic development (7).

Topper in 1990 presented a patient with VACTERL association in conjunction with possible hemifacial microsomia and fused teeth and he suggested changing the acronym of VACTERL to VACTERL-DF in recognition of these dentofacial findings (8). Digilio in 1999 found microdeletion of 22q11.2 by fluorescent in situ hybridization (FISH) in one of 15 syndromic patients with esophageal atresia(OA) and she concluded this chromosomal anomaly should be included among causative factors of VACTERL association (9). Bergmann at the Institute of Human Genetics, in Germany reported a male neonate with

congenital anomalies of VACTERL association and hemifacial microsomia (oculo-auriculo-vertebral spectrum/ OAV). In addition, striking asymmetry of the anomalies further supported the classification as part of the axial mesodermal dysplasia complex (AMDC) which possibly arises from disturbed mesodermal cell migration during early blastogenesis (10).

Khoss found a combination of malformations such as a left pulmonary artery sling, cholecystaplasia and biliary dysplasia in a patient with VACTERL association for the first time (11).

Our patient had atresia of both ears with VACTERL association.

Case Presentation

A male full term neonate with a birth weight of 2690 g, head circumference 34 cm and length 48 cm, delivered via Cesarean section was seen. There was no family history of hereditary anomalies and there was no history of drug use in pregnancy during pregnancy. The Apgar score was 7/10 one minute after birth. He had excessive salivation and also experienced several episodes of vomiting and choking and became cyanotic. He was suspected to have proximal esophageal atresia which was confirmed by looped orogastric tube in the upper pouch of the esophagus on chest X-ray. His abdominal x-ray showed gaseous distention (Figs. 1 and 2). The skeletal survey showed sacral agenesis. Cardiac exam revealed a systolic murmur grade (2/6) at the heart base compatible with patent ductus arteriosus. Sonography of the right kidney showed that it was larger than normal (24×53 cm) with multicystic lesions, (BUN= 45, Creatinine = 1.4). He also had atresia of both auricles and the external ear canal (Fig-4). Diagnostic study revealed long gap esophageal atresia. The neonate was sent to the operating room. Colostomy was done for anal atresia (Fig. 3). Gastrostomy tube replacement for long gap esophageal atresia was done by a pediatric surgeon. Post-operation mechanical ventilation was initiated for him; the patient was oliguric. Despite intensive care in the NICU, the general conditions of the neonate worsened and he finally expired. Autopsy was not permitted by the parents.

Table-1. Incidence of VACTERL defects by type(4)

V-vertebral anomaly	24.1%
Tethered cord	4.4%
Butterfly vertebra	3.5%
Vertebral fusion	4.4%
Hemivertebra	4.4%
Additional lumbar vertebra	1.8%
Additional or absent ribs	5.3%
A-all atresias	14.3%
Imperforate anus	10.7%
Duodenal atresia	3.6%
C-intrinsic heart lesion	32.1%
Ventricular septal defect (VSD)	22.3%
Atrial septal defect (ASD)	11.6%
ASD and VSD	16.1%
VSD only	7.1%
ASD only	4.5%
Tetralogy of Fallot	4.5%
Dextrocardia	3.6%
Coarctation	1.8%
Double arch	0.9%
TE-atresia distal fistula	83.0%
H type	5.4%
Pure atresia	4.5%
Double fistulas	1.8%
Atresia/proximal fistula	0.9%
Distal fistula	20.9%
R-internal urinary anomaly	17.0%
Reflux	7.1%
Horshoe kidney	6.3%
Hypospadias	5.4%
Solitary kidney (agenesis)	3.6%
Ureteropelvic obstruction	2.7%
Cryptorchidism all	2.7%
Bilateral cryptorchidism	1.8%
Unilateral cryptorchidism	0.9%
Dysplastic kidney	0.9%
L-skeletal anomalies	8.9%
Absent radius	3.5%
Digital anomalies	6.2%
Hip dysplasia	0.8%
Other-all others	10.8%
Cleft palate	4.5%
Abnl chromosomes	3.6%
Trisomy	21.8%
Cleft lip	0.9%

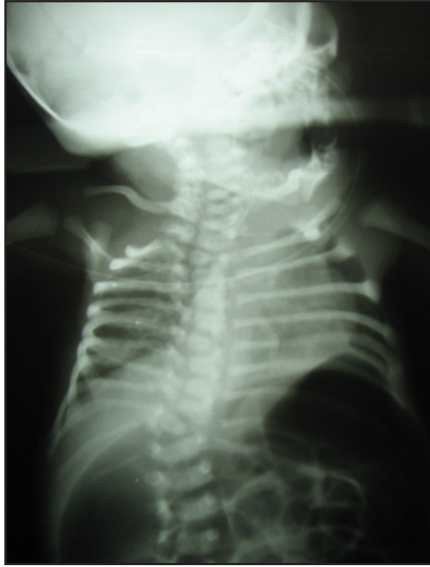

Figure -1. Chest x-ray of patient reveals vertebral anomaly, looped OG tube at the upper pouch of esophagus, gaseous distension due to tracheoesophageal fistula.

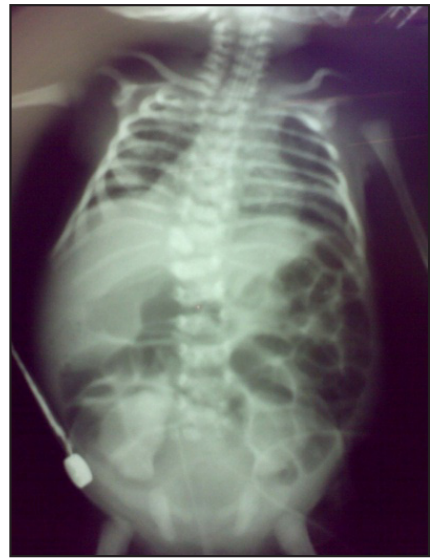

Figure -2. Abdominal x-ray of patient reveal distended abdomen without gas in rectal area because of anal atresia.

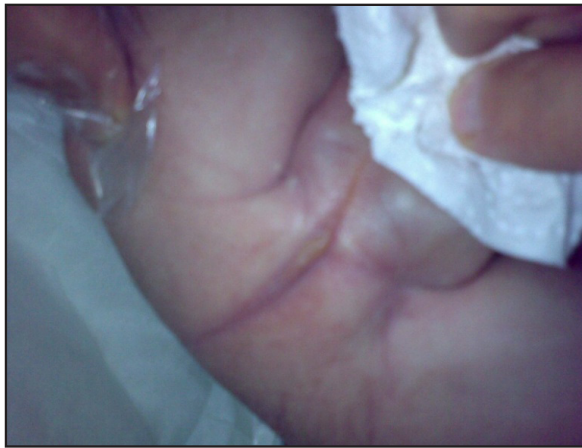


Figure -3. photograph of the patient reveal anal atresia.

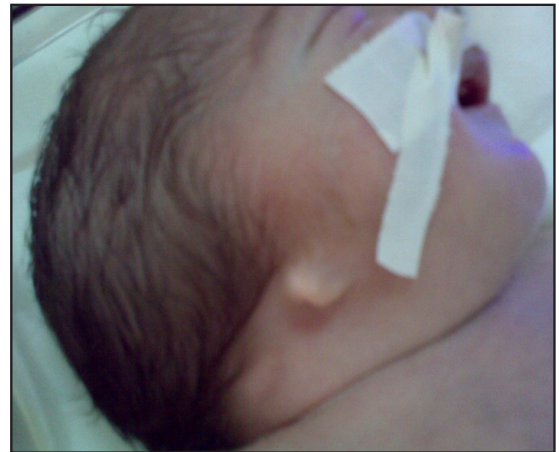

Figure -4. photograph of the patient reveal auricle atresia.

Discussion

VACTERL association is a genetic entity (1). The spectrum of anomalies described in VACTERL is quite variable. Recent reports suggested that a wide spectrum of abnormalities consisting of arch defects such as hydrocephalus, cleft palate, malformed ear (ear tags, ear pits, etc.) are seen. (1, 6)

Mullassery reported an adverse association between esophageal atresia and cleft palate as well as an increased rate of mortality in such patients with esophageal atresia, cleft lips or palate (12).

Alieferdioglu reported a neonate with VACTERL and hydrocephalus associated with central hypothyroid for the first time (1).

In 2007 Sungawa reported twins affected by VACTERL association (6).

Bergmann presented an infant with multiple congenital anomalies whose phenotype displayed an overlap between VAVTERL and hemifacial microsomia (10).

Czeizel studied the etiology of VACTERL association and VACTERL-like (combination of three or more other abnormality with VACTERL) associations. He concluded genetic factors play a role in the etiology of this heterogeneous group of multiple congenital abnormalities but not in the etiology of the VACTERL association (13). Aftimos described a newborn girl with anal atresia, renal aplasia, vertebral and rib anomalies, amelia and hemifacial microsomia. The patient demonstrated the overlap between the VACTERL association and oculoauriculovertebral dysplasia (14). Our patient had atresia of both ears; this major defect has not been report in previous studies. Our patient did not have any notable limb abnormalities.

Conclusion

VACTERL may present with additional anomalies such as ear defects, or ear atresia. Chromosomal studies should be considered in patients with esophageal atresia, for detection of deleted 22q11.2 chromosome.

Acknowledgment

The authors would like to thank Mrs. Banary for the photographs.

References

1. Aliefendioglu D, Bademci G, Keskil S, Somuncu S, Misirlioglu E, Cakmak AM. VACTERL-H associated with central hypothyroidism: a case report. *Genet Couns* 2007;

18: 331-335.

2. National Institutes of Health Clinical Center (CC) Clinical and Genetic Studies of VACTERL Association, available at: www.clinicaltrial.gov.

3. Bacino CA. Approach to congenital malformations. 2010. up to Data. available at: <http://www.uptodate.com>

4. Keckler SJ. VACTERL: An updated delineation of the spectrum and review of the literature. 2007; 23:309-313.

5. Sanders RC, Hogge WA, Wulfsberg EA, Spevak PJ. *Structural Fetal Abnormalities: the Total Picture*. 2nd ed. Saunders: Mosbey; 1996.

6. Sunagawa S. Esophageal atresia; study findings from broadened understanding of esophageal atresia: Obesity, Fitness and Wellness Week. 2007; 12: 676.

7. David A, Mercier J, Verloes A. Child with manifestations of Nager acrofacial dysostosis, and the MURCS, VACTERL, and pulmonary agenesis associations: complex defect of blastogenesis? *Am J Med Genet* 1996; 62: 1-5.

8. Topper DC, Zallen RD, Kluender RL. A dental and facial anomaly not previously reported with VACTERL association: report of case. *ASDC J Dent Child* 1990; 57: 216-219

9. Digilio MC, Marino B, Bagolan P. Microdeletion 22q11 and oesophageal atresia. *J Med Genet* 1999; 36: 137-139.

10. Bergmann C, Zerres K, Peschgens T, Senderek J, Hornchen H, Rudnik-Schoneborn S. Overlap between VACTERL and hemifacial microsomia illustrating a spectrum of malformations seen in axial mesodermal dysplasia complex (AMDC). *Am J Med Genet A* 2003 30; 121: 51-55.

11. Khoss A, Weninger M, Fruhwirt I, Gherardini R, Zeitlhuber U. [Associated abnormalities in the VACTERL syndrome--case report with autopsy findings]. *Klin Padiatr* 1985; 197: 1-4.

12. Mullassery D, Llewellyn RS, Almond SL, Jesudason EC, Losty PD. Oesophageal atresia with cleft lip and palate: a marker for associated lethal anomalies? *Pediatr Surg Int* 2008; 24: 815-817.

13. Czeizel A, Ludanyi I. An aetiological study of the VACTERL-association. *Eur J Pediatr* 1985; 144: 331-337.

14. Aftimos S, Winship I. A patient with VACTERL association, amelia and hemifacial microsomia. *Clin Dysmorphol* 1999; 8: 135-137.