

## Role of Perineal Ultrasound in Differentiating Paraurethral Cysts in Newborns

Masoud Mahdavi Rashed<sup>1</sup>, Mona Maftouh<sup>2</sup>, Seyyed Ali Alamdaran<sup>3</sup>, Moloud Moghaddasi<sup>2\*</sup>

1. Department of Radiology, Dr. Sheikh and Akbar Hospitals, Mashhad University of Medical Sciences, Mashhad, Iran

2. Radiology Department, Faculty of Medicine, Mashhad University of Medical Sciences, Mashhad, Iran

3. Surgical Oncology Research Center, Mashhad University of Medical Sciences, Mashhad, Iran

### ABSTRACT

**Background:** Paraurethral cyst or Skene's gland cyst is a rare congenital abnormality and a rare cause of paraurethral cysts resulting from Skene's gland, which has been reported in few studies so far. The Skene's duct cyst can cause urinary retention or anuria; moreover, it can appear as an inter-labial mass in neonates.

**Case report:** Our patient was a one-day-old female neonate presented with anuria and an inter-labial mass found in physical examination. The patient was referred by a pediatric surgeon to our department for sonographic evaluation. We did an ultrasound examination and made a tentative diagnosis of paraurethral cyst based on grayscale appearance and ultrasonographic criteria of the cystic lesion. The patient underwent surgery, a biopsy was obtained, and the specimen was sent for pathologic evaluation to a pediatric pathologist. The result confirmed our diagnosis as a Skene's duct cyst.

**Conclusion:** In this study, it was found that paraurethral cysts in newborns can be investigated using perineal ultrasound, which can eliminate the need for invasive surgeries.

**Keywords:** Newborn, Paraurethral cyst, Skene's cyst, Ultrasound

### Introduction

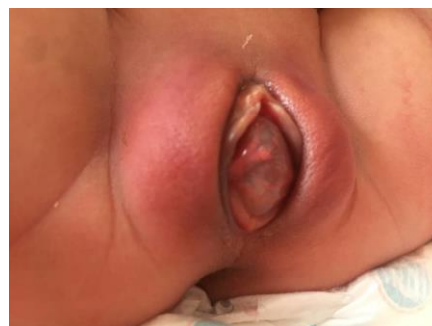Skene's gland cyst, which is a rare congenital abnormality in the female newborns, is a cystic mass adjacent to the urethral meatus (1). This cyst derives from the obstruction of the Skene's duct and presents as a small (average size: 1-2 cm), yellow, or whitish inter-labial mass. The cysts are usually diagnosed by physical examination (2). The incidence rate of this lesion is variable (about 1:2074-7242); however, it might be higher than that described in previously conducted studies (3).

There is a limited number of studies on Skene's cyst detection by ultrasound. Therefore, in the current case report, we describe the clinical application of ultrasound in Skene's cyst diagnosis and its potential value to reduce invasive surgeries for identification of this lesion.

### Case report

Our patient was a one-day-old female neonate

who presented with anuria. There was an inter-labial mass (1.5\*1.0 cm) in physical examination. The mass was cystic, oval-shaped, soft, and reddish. It was located anterior to the vaginal orifice and had covered the urethral meatus (Figure 1).

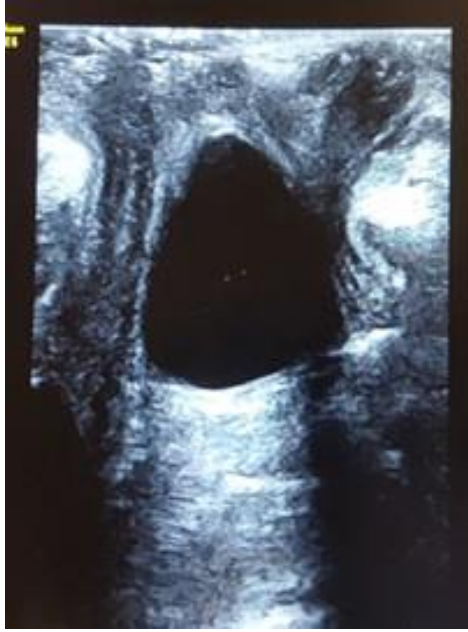

**Figure 1.** Oval-shaped and reddish Skene's cyst near the urethral meatus observed in the patient

\* Corresponding author: Moloud Moghaddasi, Radiology Department, Faculty of Medicine, Mashhad University of Medical Sciences, Mashhad, Iran. Tel: +989155221993; Email: drmoloudmoghaddas88@yahoo.com

Please cite this paper as:

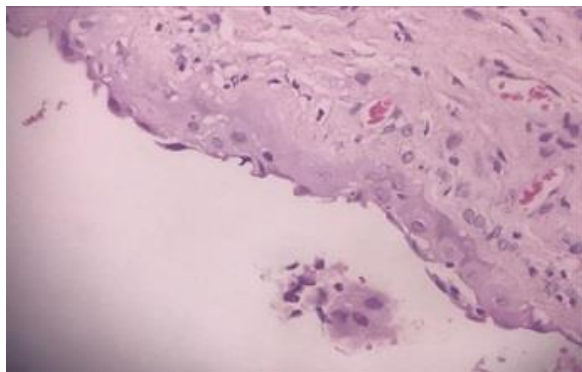
Mahdavi Rashed M, Maftouh M, Alamdaran SA, Moghaddasi M. Role of Perineal Ultrasound in Differentiating Paraurethral Cysts in Newborns. Iranian Journal of Neonatology. 2020 Dec; 11(4). DOI: [10.22038/ijn.2020.40780.1666](https://doi.org/10.22038/ijn.2020.40780.1666)



**Figure 2.** Perineal ultrasound, Cystic mass just near the urethra

We did an ultrasound examination using a high-frequency linear array transducer (12-5 MHz). Trans-perineal ultrasound showed a 14-mm cystic lesion without any solid component located posterior to the urethra and inferior to the vagina (Figure 2).

Abdominopelvic sonography did not show any hydronephrosis and other urogenital abnormalities or anomalies. We described the mass as a paraurethral cyst in the ultrasonographic evaluation, and the patient underwent surgery for the resection of the cyst. The specimen was sent to a laboratory, and the pediatric pathologist reported the presence of a deep benign cyst lined by squamous cells and a vaginal wall lined by squamous mucosa at the luminal surface. The final diagnosis was Skene's duct cyst (Figure 3).



**Figure 3.** Pathologic examination showed a cyst lined by squamous cells

## Discussion

Skene's duct cysts are rare causes of interlabial masses, especially in newborns (4). Maternal exposure to estrogen, obstruction or stenosis of the duct, and dislocation of the urothelium have been suggested as causes (5). Patients with Skene's duct cysts can be misdiagnosed with an imperforate hymen, urethral diverticulum, urethral prolapse, prolapsed ectopic ureterocele, and rhabdomyosarcoma of the vagina (4, 5). These conditions should be managed by different approaches, and ultrasound can be utilized to differentiate them (6). According to previously conducted studies, there are controversies regarding the use of ultrasound as an additional diagnostic tool for paraurethral cysts. However, in cases of urinary outflow obstructions, the majority of the researchers considered it necessary to exclude associated renal or bladder abnormalities (7).

Pathologically, Skene's duct cysts result from congenital or acquired obstruction of paraurethral or Skene's glands in the distal urethra. These cases can be asymptomatic or present with a mass at the vaginal introitus which is lined by squamous epithelium resulting from urogenital sinus origin (8). There are several treatment options, including observation, needle aspiration and drainage, excision, unroofing, and marsupialization which are often without recurrence (4, 5). It is worth mentioning that surgical excision was performed in this study.

## Conclusion

In this study, it was found that paraurethral cysts in newborns can be investigated using perineal ultrasound, which can eliminate the need for invasive surgeries.

## Acknowledgments

The authors would like to express their deep and sincere gratitude to Dr. Marjan Joodi for performing the surgery. It was a great privilege to study under her guidance. Moreover, they would also like to thank Dr. Paria Dehghan for evaluating the biopsy samples.

## Conflicts of interest

There is no conflict of interest regarding the publication of the study.

## Funding

This study was supported financially by Mashhad University of Medical Sciences, Mashhad, Iran

## References

1. Lee NH, Kim SY. Skene's duct cysts in female newborns. *Journal of pediatric surgery*. 1992; 27(1):15-7.
2. Nakamura E, Shintaku S, Horii M, Manabe H, Hirano Y, Muroto K. Early regression of paraurethral cyst in a neonate. *Pediatrics & Neonatology*. 2014;55(3): 225-7.
3. Costantino E, Ganesan GS. Skene's gland cyst as an inter-labial mass in a newborn girl. *BMJ Case Reports*. 2016;2016:bcr2016215042.
4. Moralioglu S, Bosnali O, Celayir AC, Şahin C. Paraurethral Skene's duct cyst in a newborn. *Urology annals*. 2013;5(3):204.
5. Dhapodkar S, Homayoon K. Paraurethral cysts in a female newborn. *Open Journal of Urology*. 2011;1(03):48.
6. Schoellnast H, Lindbichler F, Riccabona M. Sonographic Diagnosis of Urethral Anomalies in Infants. *Journal of ultrasound in medicine*. 2004;23(6):769-76.
7. Fathi K, Pinter A. Paraurethral cysts in female neonates. Case reports. *Acta Paediatrica*. 2003; 92(6):758-9.
8. Mills SE, Greenson JK, Hornick JL, Longacre TA, Reuter VE. *Sternberg's diagnostic surgical pathology*. Lippincott Williams & Wilkins; 2015 Jan 21.