

Aplasia Cutis Congenita (ACC) and Seizure in a Premature Neonate: Could It Be a New Neurocutaneous Syndrome?

Alireza Tavasoli ^{1*}, Mahmoudreza Ashrafi ¹, Mahmoud Mohammadi ¹, Mehrdad Mirza Rahimi ², Jafar Khalafi ²

¹ Department of Pediatrics, School of Medicine, Tehran University of Medical Sciences, Tehran, Iran

² Department of Pediatrics, School of Medicine, Ardebil University of Medical Sciences, Ardebil, Iran

ABSTRACT

One of the few conditions associated with skin ulceration in the neonatal period is aplasia cutis congenita (ACC). ACC or congenital absence of the skin is considered an uncommon anomaly. This malformation commonly appears on the scalp as a solitary lesion, though it can be seen in other surfaces of the body such as the trunk, limbs and face. ACC can be associated with other physical anomalies such as defects of the heart, gastrointestinal system, genitor-urinary system, central nervous system, and also in association with umbilical hernia. There are very few reports of ACC and seizure as a prominent clinical manifestation. In this study, we present a premature neonate with ACC lesions on the right side of the nose, on the right hand and the foot, together with frequent seizures with onset within the initial hours of the birth. Laboratory testing and brain MRI of the patient revealed no significant results. This case may present a new group of ACC classification, or a new neurocutaneous syndrome.

Keywords: Aplasia Cutis Congenita, Neurocutaneous Syndrome, Seizure

Introduction

Aplasia cutis congenital (ACC) or congenital absence of skin is rare anomaly of the skin. This malformation commonly appears on the scalp as a solitary lesion, though it can be seen in other surfaces of the body such as the trunk, limbs and face. Its shape may be circular, oval, linear or satellite with a size range of 0.5-10 cm (1, 2). Structurally, these lesions with sharp borders, absence of epidermis and papillary dermis, are non-inflammatory; otherwise, they may progress to deeper layers resulting in loss of deep dermis, the subcutaneous tissue, and even, on the scalp, may involve the skull and dura (2). No racial or sexual predilection has been reported for this disorder (2-4). In literature review, the frequency of ACC has been reported in 0.5 to 3 cases in every 10,000 births (1-3, 5, 6). There are very few reports of ACC and seizure as a prominent clinical manifestation. Wu *et al* reported an infant with refractory seizures in association with aplasia cutis congenital, in 2008. In this study, we present a premature neonate with (frequent) seizure onset within the initial hours of the birth,

and with asymmetric ACC lesions on the right side of the nose, the right hand, and the foot.

Case report

Our case was a female premature neonate who was born at 31 weeks of gestational age, after spontaneous vaginal delivery. Apgar score was 4 at 1st minute, and 5 at 5th minute. She was the second child of consanguineous parents and her mother had an uneventful pregnancy, with no history of drug abuse; though the mother had a positive history of abortion at the second trimester of pregnancy, before the delivery of the first child. Also, there was no history of other cases or hereditary diseases in the families of the parent. Birth weight and head circumference of our patient were 1.75 Kg and 28 cm, respectively. She was admitted in NICU of the hospital, due to low birth Apgar score, and respiratory distress, and was treated with mechanical ventilation. Physical examination of the patient revealed three membranous wounds and skin lesions with well-demarcated borders; no inflammations on the

* Corresponding author: Pediatric Neurologist, Children Medical Center, Tehran University of Medical Sciences, Tehran, Iran; Email: dralit73@yahoo.com

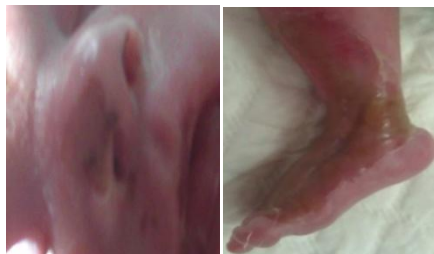

Figure 1. Two skin lesions (Aplasia cutis congenita) with sharp borders on the right side of the nasal blade and distal portion of the right foot. Image of right hand skin lesion had poor quality and is not shown here.

right side of the nose and the distal portion of right hand and foot were observed.

The size of the lesion on the nose was small (about 0.7*1 cm), although they were larger on the right hand and foot (greater than 5 cm) (Figure 1). Dermatology Consultation confirmed that these lesions were aplasia cutis congenital (ACC). There was no history of using vacuum extraction, and forceps, or obstetric trauma during delivery. About <12 hr after patient's birth, her multifocal clonic seizures started (first right side of the body, and then the left side) with high frequency.

We used vitamin B6, phenytoin, and finally a suitable loading and maintenance dose of phenobarbital for controlling the seizures, step by step; the seizures were controlled about 12 hr after the onset. Digital EEG monitoring was performed for the patient, which showed Suppression-burst (S-B) variant (Figure 2). Also, brain MRI without contrast was performed which revealed that gross structural abnormality and myelination process were not within the normal limit for premature infants (Figure 3).

Upon admission, laboratory investigations indicated no significant results of the blood and cerebrospinal fluid. After 2 days of birth, the respiratory condition of the patient deteriorated without any significant clinical seizures, and she died despite the complete resuscitation.

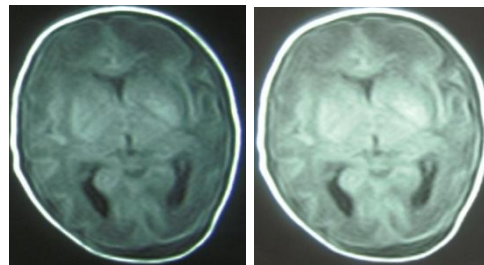


Figure 3. T1 and T2 FLAIR sequences of brain MRI of the patient (without Gad). There were no significant findings in these images.

Discussion

The first cases of ACC were described by Cordon in 1767, as a limb skin lesion, and by Campbell in 1826, as a scalp lesion (3). Although the etiology, genetic location and inheritance pattern of this disorder are not exactly specified, sporadic pattern along with autosomal dominant and autosomal recessive inheritance patterns in familial cases have been shown in reported cases (1, 3-5, 7).

Some factors proposed as etiology for this disorder are as follows: genetic predisposition, vascular events, amniotic etiologies, intrauterine infections (varicella-zoster virus, herpes simplex virus, and congenital rubella syndrome), specific drugs (methimazole, benzodiazepines, sodium valproate, diclofenac, misoprostol, methotrexate, carbimazole, and some angiotensin-converting-enzyme inhibitors,) and teratogens (cocaine, heroin and alcohol) (1, 3, 5, 7-9).

ACC can be seen with other physical anomalies such as defects of the heart, gastrointestinal system, genitor-urinary system, central nervous system, and also in association with umbilical hernia (1, 3). In addition, ACC can be seen in association with some genetic and chromosomal syndromes, including down syndrome, 4p trisomy, trisomy 13, Adams-Oliver, Bart, Ellis-van Creveld, Johanson-Blizzard, Kabuki, and Setleis syndromes, and also 46XY gonadal

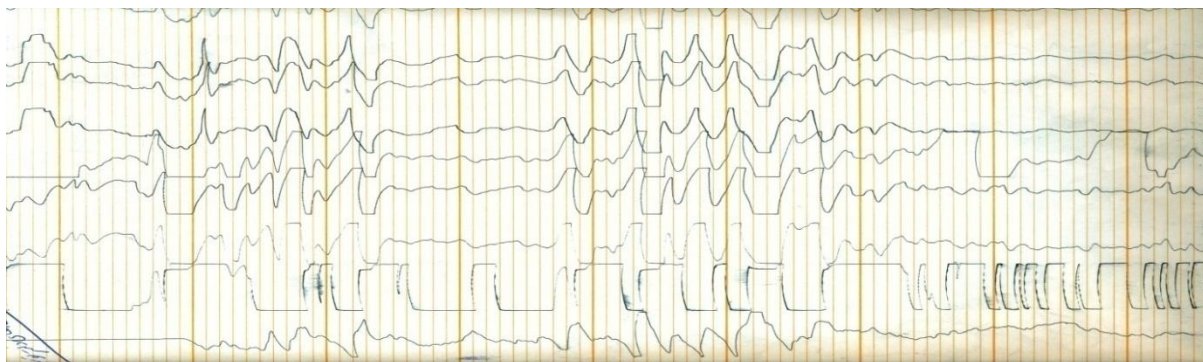


Figure 2. As it is observed in capture of EEG, it seems to be a suppression-burst(S-B) variant.

Table 1. Frieden's classification for ACC and its inheritance pattern (2, 3, 11)

Group	Type of ACC	Inheritance pattern
1	Scalp ACC without multiple anomalies	AD or sporadic
2	Scalp ACC with associated limb anomalies	AD
3	Scalp ACC with associated epidermal-organoid nevi	Sporadic
4	ACC overlying embryologic malformation	Depends on the malformation
5	ACC with fetus papyraceous or placental infarct	Sporadic
6	ACC associated with epidermolysis bullosa	Depends on EB type
7	ACC localized to extremities without blistering	AD or AR
8	ACC caused by teratogens	Not inherited
9	ACC associated with malformation syndromes	Depends on the syndrome

AD: Autosomal dominant, AR: Autosomal recessive, EB: Epidermolysis bullosa

dysgenesis (1-3). In the presented case, there was no positive history of ACC in the family, and the mother had not used any drugs during pregnancy.

ACC can be seen as a solitary lesion or multiple lesions on different surfaces of the body such as the scalp, face, trunk and limbs; although the solitary scalp lesion is the most common (1, 3, 6, 10, 11), and is sometimes superficial. In 15% of cases, the scalp lesions are deeper with involvement of skull bone and dura, therefore the risks of infection, hemorrhage and dural sinus thrombosis increase (12). Small and superficial lesions heal spontaneously with hairless scars and alopecia. Conservative treatments such as using local ointment or cream (silver sulfadiazine or bacitracin) have been recommended for these cases (3, 5, 12). Large and deep lesions may need surgical interventions, therefore therapeutic plans depend on the site of lesion, its size, related bone defects and the clinical condition of the patient (1, 3, 5, 8).

Physical examination of our patient showed asymmetric and superficial skin lesions with a membranous coverage on the right side of the body, namely right nose blade and distal portions of right upper and lower extremities. X-ray of the affected limbs showed no bone defects in association with skin lesions. No other major or minor anomalies were observed in this patient.

Frieden classified ACC into nine groups in 1986, based on the site and number of the lesions, inheritance pattern, and associated syndromes or malformations (2-4, 11). (Table 1) Based on this classification, patients in group 3 have some neurological manifestations such as seizures, and mental retardation, in association with epidermal, or sebaceous (organoid) nevus (2, 11); although our patient cannot be classified in this group because of no scalp lesions. On the other hand, group 4 also includes some patients with nervous system malformations such as meningomyelocele, porencephaly, leptomenigeal angiomatosis, cranial stenosis and spinal dysraphism (2, 10, 11). Of course the presented case does not belong to this group, either (4), based on the physical

examination and absence of scalp ACC. Group 7 consists of patients who have limb skin lesions, but ACC of the face skin is not mentioned in this group. Our patient suffered from ACC of the extremities (upper and lower limbs of the right side of the body), and his face. It seems that we cannot assign our patient to any of the nine groups introduced by Frieden. This case may present a new group of ACC classification, or a new neurocutaneous syndrome.

It is possible that seizures in this patient be caused by factors such as prematurity or hypoxic-Ischemic encephalopathy (HIE). Seizures of this patient started within the initial hours of the birth (<12 hr), and therefore they occurred earlier than the seizures in HIE. In addition, seizures in this patient had not responded to therapeutic doses of vitamin B6. Other abnormal laboratory testing, also were not found in this patient. Although, in this patient, the presence of ACC in the limbs and face, along with seizure is a novel condition.

Acknowledgements

The authors would like to thank the Vice-Chancellor for Research of Tehran & Ardebil University of Medical Sciences

References

1. Iljin A, Kruk-geromin J. Aplasia cutis congenita. *Adv Clin Med.* 2010; 19(1):121-5.
2. Crowe MA, Elston DM. Aplasia cutis congenita. 2012. Medscape. Available at: <http://emedicine.medscape.com/article/1110134-overview>.
3. Konjenita AK. Aplasia cutis congenita associated with multiple congenital anomalies: Case report. *Turkish neurosurgery.* 2010; 20(1): 66-8.
4. Crowe M. Aplasia cutis congenita. 2006. Medscape. Available at: <http://emedicine.com/derm/topi-c32.htm>
5. Wu PC, Jiang JP, Wang CC, Chen SJ. A rare case of Aplasia cutis congenita with refractory seizures. *Pediatr Neurol.* 2008; 39:435-7.
6. Pajaziti L, Rexhepi S, Shatri-Muçça Y, Ferizi M. The role of diclofenack on inducing of Aplasia cutis congenita: a case report. *Case journal.* 2009, 2:150.

7. Mihçı E, Erişir S, Taçoş Ş, Lüleci G, Alpsoş E, Oygür N. Aplasia cutis congenita: three cases with three different underlying etiologies. *Turk J Pediatr.* 2009; 51(5):510-4.
8. Martínez-Lage JF, Almagro M, Hernández FL, Poza M. Aplasia cutis congenita of the scalp. *Childs Nerv Syst.* 2002; 18:834-7.
9. Iwayama H, Hosono H, Yamamoto H. Aplasia cutis congenita with skull defect in a monozygotic twin after exposure to methimazole in utero. *Birth Defects Research Part A: Clinical and Molecular Teratology.* 2007; 79(10): 680-4.
10. İzci M, Gonul M, Secer HI, Gönül E. Aplasia cutis congenita: A rare cutaneous sign of split cord malformations. *International journal of dermatology.* 2007; 46(10):1031-5.
11. Fagan LL, Harris PA. Sporadic Aplasia cutis congenita. *Pediatr Surg Int.* 2002; 18:454-7.
12. Benjamin LT, Trowers AB, Schachner LA. Giant Aplasia cutis congenita without associated anomalies. *Pediatric Dermatology.* 2004; 21(2): 150-3.