

# Coarse Tremor as the Only Sign of Perinatal Hemorrhagic Stroke: A Case Report

Sina Karamimagham<sup>1</sup>, Maryam Poursadeghfard<sup>2\*</sup>

1. Neonatal Research Center, Shiraz University of Medical Science, Shiraz, Iran  
2. Clinical Neurology Research Center, Shiraz University of Medical Sciences, Shiraz, Iran

## ABSTRACT

**Background:** Tremor which is the most common abnormal movement in the neonatal period might be a benign condition or the result of pathologic events and is divided into two subtypes, namely fine tremor and coarse tremor. Fine tremor is usually benign and results from some metabolic disturbance, such as hypoglycemia. On the other hand, coarse tremor is an indicator of brain insult and should be regarded as a central pathology comparable to intracranial hemorrhage and hypoxic-ischemic encephalopathy and requires further evaluations. Stroke is one of the most important associated pathologies that are readily missed in the neonatal period. The possibility of stroke should be suspected in all newborns in the presence of coarse tremor.

**Case report:** Here, we will present a newborn with perinatal hemorrhagic stroke who was in good condition after birth with Apgar score of 9 and normal vital signs, birth weight, head circumference, length, and primitive reflexes; however, he had coarse tremor in both upper extremities in physical examination as the only sign of the hemorrhagic stroke.

**Conclusion:** It is recommended that neonates with coarse tremor be investigated more carefully to rule out the structural brain pathology.

**Keywords:** Hemorrhagic stroke, Ischemic stroke, Jitteriness, Prenatal stroke, Tremor

## Introduction

Tremor which is the most common abnormal movement in the neonatal period is defined as an involuntary rhythmic and oscillatory movement with equal amplitude around a fixed axis. Jitteriness refers to recurrent tremor sometimes mistaken for seizure disorders. Nonetheless, it is not a virtual seizure and is considered a kind of abnormal movement in newborns (1, 2). Jitteriness and tremor in neonates may be benign or pathologic. In the benign tremor, newborns do not have any perinatal complications and physical examinations ensure wellness and good health. In contrast, hypoglycemia, hypocalcemia, hypoxic-ischemic encephalopathy, sepsis, hypothermia, intracranial hemorrhage, drug withdrawal, and hyperthyroidism are pathological conditions that could be associated with pathologic tremor(2).

Tremor is divided into two subtypes, namely fine tremor with a frequency greater than 6 Hz

and amplitude lower than 3 cm, and coarse tremor with lower frequency rate and higher amplitude (equal or greater than 3 cm) (1, 2). The fine tremor is known as a benign sign and usually results from some metabolic disturbance, such as hypoglycemia. On the contrary, coarse tremor is important and should be regarded as a central pathology comparable to intracranial hemorrhage and hypoxic-ischemic encephalopathy, and requires further evaluations. Here, we will present a newborn with perinatal stroke (PS) who was apparently normal except a coarse tremor in physical examination.

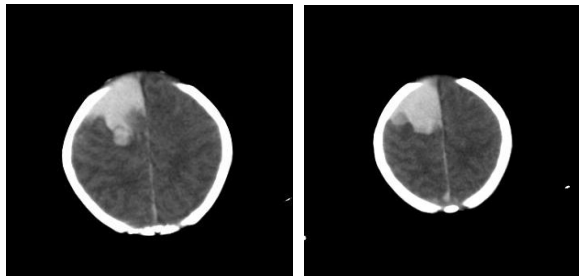
## Case report

The study case is a one-day-old male neonate who was vaginally delivered at the 39<sup>th</sup> week of gestation from a 32-year-old mother (gravid 3, live 2 and abortion 0). His mother had good

\* Corresponding author: Maryam Poursadeghfard, Clinical Neurology Research Center, Department of Neurology, Motahhari Clinic, Nemazee Square, Shiraz, Iran. Tel: +987136121065; Email: [poursadegh@sums.ac.ir](mailto:poursadegh@sums.ac.ir), [poursadra@gmail.com](mailto:poursadra@gmail.com)

Please cite this paper as:

Karamimagham S, Poursadeghfard M. Coarse Tremor as the Only Sign of Perinatal Hemorrhagic Stroke: A Case Report. Iranian Journal of Neonatology. 2019 Dec; 10(4). DOI: [10.22038/ijn.2019.37692.1583](https://doi.org/10.22038/ijn.2019.37692.1583)



**Figure 1.** Axial views of the brain CT scan show a large hyperdense area in the right frontoparietal lobe indicative of intra-parenchymal hemorrhage

antenatal care and uncomplicated pregnancy with normal routine blood tests, negative HBsAg and Venereal Disease Research Laboratory test (VDRL). In addition, the patient's parents were not consanguineous. The only finding of the antenatal ultrasound scan at the 22<sup>nd</sup> week of gestation was a 10 millimeter-choroid plexus cyst in his fetus brain which was resolved in the post-natal brain sonography. The neonate was born in a good condition with Apgar score of 9 at the first minute of life. He received one-milligram vitamin K via intramuscular injection. His recorded vital signs included represented respiratory rate: 45/min, pulse rate: 145/min and body temperature: 37 °C; moreover, his blood pressure was reported to be normal. Clinical examination, including all primitive reflexes, was normal except for the coarse tremor in both upper extremities. Therefore, cranial ultrasound scan performed within the first few hours of life revealed a hyperechoic area in the white matter of the right frontal lobe measuring 28×18 mm with edematous cortex suggestive of intracranial hemorrhage (ICH), intra-parenchymal type. In the second day of life, computed tomography (CT) scan of the brain without contrast media was carried out which confirmed ICH in the right fronto-parietal lobe (Figure 1). Complete blood count (CBC), platelet count (207000), blood glucose, calcium, blood urea nitrogen (BUN), creatinine, Na, K, and thyroid-stimulating hormone (TSH) were all normal. Prothrombin time (PT), partial thromboplastin time (PTT) and international normalized ratio (INR) were reported as 12(control 12), 34 and 1.1, respectively. Equally important, direct and indirect Coombs tests were negative.

In the thrombophilia screening tests, protein C was 57 IU/dl (normal in term infant), protein S: 60IU/dl (normal range), anti-thrombin III: 93% (normal), factor 5 Leiden (APC-R): 215sec (negative), and blood homocysteine level: 13.3 micromole/l (normal range). Moreover,

electroencephalogram (EEG) was normal. During hospital admission, serial cranial ultrasounds were performed and all of them revealed no progression in ICH. He was discharged with a clinically good condition on full enteral breastfeeding after 5 days.

## Discussion

Our patient presented with jitteriness in the first few hours of his life. Jitteriness is an abnormal movement mainly comparable to tremulous; however, it could occasionally be represented in a clonus form(1). In the first 72 hours of life, about two-thirds of normal neonates demonstrated variable degrees of fine tremor due to immature inhibition of the spinal cord and elevated levels of circulating catecholamine. Benign tremor disappeared when the neonate sucked the examiner's finger as a pacifier.(2, 3) Unlike neonates, tremor in other age groups and adults usually indicates pathology within the cerebellum, basal ganglia, thalamus, and red nucleus. Huntsman et al. recommended that jitteriness in the neonatal period should be evaluated based on perinatal history and physical examination. On the other hand, if physical examination ensures wellness and good health and absence of a history of prenatal complications, only blood glucose measurement suffices. Nonetheless, if the neonate appears unwell, has a coarse tremor or history of the perinatal complications or tremor does not subside with suckling and bland, further investigations are recommended, including sepsis workup, urine drugs screening, neuroimaging, thyroid screening tests, and metabolic workup. Without the history of perinatal complications, neonates with fine or coarse jitteriness have normal neurodevelopmental outcome(3).

Risk factors for pathologic jitteriness in the neonatal period include neonatal asphyxia, intraparenchymal bleeding, maternal substance abuse, low birth weight, premature delivery, intrauterine growth failure, diabetic mother, electrolyte imbalance, metabolic disturbance, sepsis, and hypothermia(3).

Our patient had tremor in the base of perinatal hemorrhagic stroke. PS presents differently from adults' stroke(4). In neonates, focal neurologic signs are rare(5). The clinical presentations of PS vary from overt seizures to the subtle or non-specific manifestations, including poor feeding, apnea or grunting, lethargy, hypotonia, tremor, encephalopathy, and occasionally feeding difficulties. Furthermore, it could sometimes be

asymptomatic (incidentally diagnosed by brain imaging) (1, 5, 6). In this regard, Joseph et al. reported four cases of neonatal stroke with variable clinical presentations. Their first case was a premature neonate delivered by C-section who presented with respiratory and cardiovascular failure. The next two cases were full-term newborns that developed respiratory problems and seizures. The last presented case was also a term-delivered and intrauterine growth retardation (IUGR) boy with episodes of central apnea requiring stimulation. In all these four patients, follow-up evaluation demonstrated cerebral sinus venous thrombosis as a cause of symptoms(7). In another case report in 2017, progressive respiratory failure was started in a term girl ten minutes after delivery and an acute ischemic lesion in the areas of the left middle and posterior cerebral arteries was detected the next day(8).

Seizure is a common presentation of neonatal stroke which should be differentiated from jitteriness presented in many instances in the normal newborns(5, 9) which requires a high level of suspicion to diagnosis. In 2010, Gelfand et al. reported an apparently normal patient with two episodes of transient unilateral rhythmic clonic movements within the first 24 hours of life. Following extensive work-up, an acute infarct in the angular branch of the right middle cerebral artery was detected (4).

Although physical examination confirmed good health in the neonate, coarse tremor led us to further work-up. On the other hand, coarse tremor was the only presenting sign of brain insult. In fact, most of the abovementioned cases were the result of such complicated pregnancy as gestational diabetes, decreased amniotic fluid, and premature rupture of membranes. However, as mentioned earlier, our case had a normal gestational period and born with uncomplicated vaginal delivery.

Although some of the neonates may not look severely ill during an acute PS, the possibility of stroke should be suspected in all newborn infants with focal seizures or other signs of acute brain insult even despite their good general condition to prevent under-diagnosis. Many of these infants were born with uncomplicated pregnancy and delivery without any perinatal risk factors(1). In 2004, Wang et al. conducted a study on a total of 2309 apparently normal term babies by brain sonography. They realized six babies with major brain lesions, including three cases of intracranial hemorrhage and one patient with middle cerebral

artery infarction(10).

Perinatal stroke has no clear cause in many instances. Cranial Ultrasound Scan (CUS) is the first imaging modality for evaluation(11). CUS may show abnormalities strongly suggestive of brain infarction and serial scanning is advocated in this situation,(1). most hemorrhagic strokes are diagnosed using trans-fontanelar sonography; however, ischemic injuries are hardly visualized(9) and magnetic resonance imaging(MRI) confirms the diagnosis. Although computed tomography (CT) may be utilized, it not considered the best diagnostic option(1, 9) and further evaluation is needed to determine the risk factors following diagnosis of PS(5). In many cases; however, no risk factors will be found (5). Thrombophilic states, such as hyper-homocysteinemia or deficiency in protein C or S, require specific therapies. In addition, electroencephalography (EEG) and MRI can be efficiently used for prognosis.

In our patient, prenatal maternal sonography indicated a choroidal plexus cyst with a diameter of 10 mm at the 22<sup>nd</sup> week of gestation which was revealed in the post-natal brain sonography. Antenatal choroid plexus cyst is often benign and transient and is detected in 1.2% of all pregnancies; however, there exists a small additional risk for trisomy 18(12, 13). The patient was born by an eventless vaginal delivery. On the first day of life, right frontoparietal lobe hemorrhage with diameters of 28×18mm was reported in sonographic imaging of the brain. The current study aimed to warn about some presumed normal movements in the neonatal period, such as coarse tremor, that may be a sign of intracranial pathology like PS; therefore, these neonates are better to be evaluated at least by a CUS.

## Conclusion

The clinical presentation of PS may be subtle, and many of these newborns remain undiagnosed in the neonatal period. Coarse tremor may be a presenting sign of brain insult, such as stroke. Accordingly, it is recommended that each neonate with coarse tremor be investigated more carefully to rule out the structural brain pathology.

## Acknowledgments

Our sincere appreciation and thanks go to Shiraz University of Medical Sciences, as well as the Center for Development of Clinical Research of Nemazee Hospital and Dr. Nasrin Shokrpour for

editorial assistance.

### Conflicts of interests

The authors declare no conflicts of interest regarding the publication of this study.

### References

1. Paddock M, Demetriou A, Nicholl R. Are we considering neonatal stroke early enough in our differential diagnosis? *J Neonatal Perinatal Med.* 2014; 7(4):293-9.
2. Huntsman RJ, Lowry NJ, Sankaran K. Nonepileptic motor phenomena in the neonate. *Paediatr Child Health.* 2008; 13(8):680-4.
3. Armentrout DC, Caple J. The jittery newborn. *J Pediatr Health Care.* 2001; 15(3):147-9.
4. Gelfand AA, Glass HC, Marco EJ, Ferriero DM. Focal clonic seizures suggest stroke in a newborn. *Neurol Bull.* 2010; 2(1):7-11.
5. Gleason CA, Juul SE. *Avery's diseases of the newborn e-book.* New York: Elsevier Health Sciences; 2017.
6. Hagberg H, Edwards AD, Groenendaal F. Perinatal brain damage: the term infant. *Neurobiol Dis.* 2016; 92:102-12.
7. Joseph S, Angelis D, Bennett R, Kola B, Hughes A. Variability in clinical presentation of neonatal stroke: report of four cases. *Case Rep Neurol Med.* 2017; 2017:5215686.
8. Pulver M, Juhkami K, Loorits D, Ilves P, Kuld J, Öglane-Šlik E, et al. Symptomatic neonatal arterial ischemic stroke with prenatal and postnatal neuroimaging. *Child Neurol Open.* 2017; 4:2329048X17730460.
9. Gacio S, Muñoz Giacomelli F, Klein F. Presumed perinatal ischemic stroke: a review. *Arch Argent Pediatr.* 2015; 113(5):449-55.
10. Wang LW, Huang CC, Yeh TF. Major brain lesions detected on sonographic screening of apparently normal term neonates. *Neuroradiology.* 2004; 46(5):368-73.
11. Chang YC, Lee CY, Chen CH, Ku YC, Wang JD. Cyanosis as a signal of perinatal stroke: findings at ultrasound and MRI. *Iran J Pediatr.* 2015; 25(3):e533.
12. Walkinshaw SA. Fetal choroid plexus cysts: are we there yet? *Prenat Diagn.* 2000; 20(8):657-62.
13. Demasio K, Canterino J, Ananth C, Fernandez C, Smulian J, Vintzileos A. Isolated choroid plexus cyst in low-risk women less than 35 years old. *Am J Obstet Gynecol.* 2002; 187(5):1246-9.