

# Successful Repair of Neonatal Tricuspid Regurgitation Due to Papillary Muscle Rupture: A Rare Case

Hasan Birjandi<sup>1</sup>, Mahmood Hosseinzadeh Maleki<sup>2\*</sup>, Hosein Akhavan<sup>1</sup>

1. Department of Pediatric Heart Disease, Emam Reza Hospital, Mashhad University of Medical Sciences, Mashhad, Iran  
2. Department Of Cardiac Surgery, Emam Reza Hospital, Mashhad University of Medical Sciences, Mashhad, Iran

## ABSTRACT

**Background:** Neonatal rupture of the chordae of the tricuspid valve with severe regurgitation is scarce and devastating.

**Case report:** Here, we report the case of a full-term male neonate presented with cyanosis caused by severe tricuspid regurgitation due to anterior leaflet papillary muscle rupture. Following initial stabilization by the infusion of prostaglandins E1, successful early repair was achieved.

**Conclusion:** Early diagnosis of the tricuspid valve papillary muscle rupture is critical, and early surgical repair have a good result during early post-operative period.

**Keywords:** Neonatal cyanosis, Papillary muscle rupture, Tricuspid valve regurgitation

## Introduction

Severe tricuspid regurgitation (TR) caused by a flail leaflet is a scarce cause of neonatal cyanosis. If not recognized early, the consequences can be fatal (1,2). We present the case of a full-term male neonate with cyanosis and dyspnea caused by severe TR as a result of anterior leaflet papillary muscle rupture. After prostaglandin E1 infusion was stabilized to maintain ductal patency, we achieved successful early repair using polytetrafluoroethylene. Early diagnosis and timely surgery can save lives.

## Case report

A 3500 gm full-term male neonate was born through meconium-stained amniotic fluid. The first- and fifth-min Apgar scores were reported as 7 and 8, respectively. Physical examination showed a grade III/VI diffuse pansystolic murmur. The newborn was cyanotic, and oxygen saturation was obtained at 85%. Two-dimensional echocardiography revealed severe tricuspid regurgitation (TR) as a result of flail anterior leaflet and patent ductus arteriosus. We compromised the antegrade pulmonary flow and noted a right-to-left shunting through a patent

foramen ovale.

When he was 8 days old, cyanosis worsened due to impending ductal closure. He was intubated, and prostaglandin E1 was infused (0.2 µg/kg/min) after cardiopulmonary resuscitation. Subsequently, the condition was stabilized, and surgery was performed. The patent ductus was ligated, and the right atrium was opened under mild hypothermia with cold crystalloid cardioplegic cardiac arrest. A flail tricuspid anterior leaflet caused by papillary muscle tip rupture was confirmed (Figure 1A, B). The papillary muscle demonstrated fibrotic and calcified change. The length of the septal leaflet chordae was measured, and chordae were reimplemented to the tip of the papillary muscle with pledget 5-0 polytetrafluoroethylene suture. Tricuspid annuloplasty was not required since the annulus was not dilated. The patent foramen ovale remained open for pop-off purposes. After 30 days, two-dimensional echocardiography showed mild tricuspid valve regurgitation.

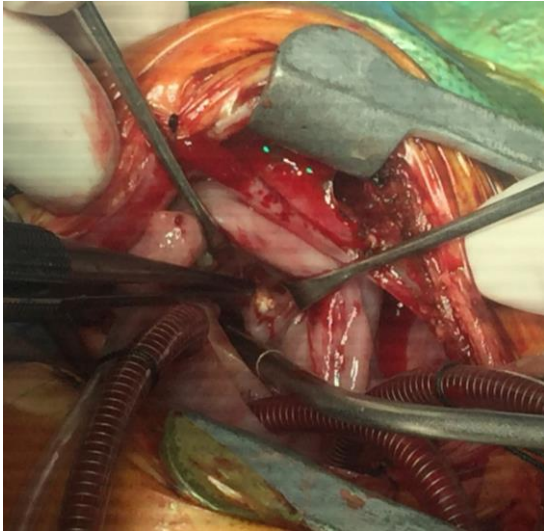
## Discussion

In the neonatal period, isolated TR is a rare

\* Corresponding author: Mahmood Hosseinzadeh Maleki, Department of Pediatric Heart Disease, Emam Reza Hospital, Mashhad University of Medical Sciences, Mashhad, Iran. Tel: 09155127487; Email: mahmoodhosseinzadeh@yahoo.com

Please cite this paper as:

Birjandi H, Hosseinzadeh Maleki M, Akhavan H. Successful Repair of Neonatal Tricuspid Regurgitation Due to Papillary Muscle Rupture: A Rare Case. Iranian Journal of Neonatology. 2020 Dec: 11(4). DOI: [10.22038/ijn.2020.44225.1732](https://doi.org/10.22038/ijn.2020.44225.1732)

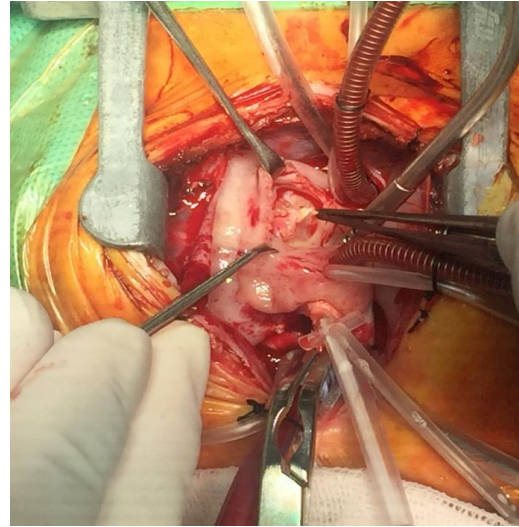


**Figure 1A.** Tip of the papillary muscle with fibrotic change and yellowish color

condition that can cause intractable hypoxia and cyanosis. The flail tricuspid leaflet due to spontaneous papillary muscle or chordae rupture in newborns with a normal heart structure is potentially fatal and requires full medical treatment (1-3).

Myocardial ischemia resulting from birth asphyxia, premature ductal closure, endocarditis, maternal autoimmune disease, and thromboembolism may cause chordae or papillary muscle rupture of the tricuspid valve in neonates (4). In general, the anterior papillary muscle of the tricuspid valve is prone to ischemia due to its high oxygen demand, its distal extreme of the coronary circulation, and diastolic coronary perfusion during elevated right ventricular pressure. In our patient, the history of perinatal meconium staining was clear. There was no autoimmune disease or associated drug history during late pregnancy.

Although the prostaglandin E1 infusion can control cyanosis and desaturation, early repair of the tricuspid valve is still mandatory. The technique of polytetrafluoroethylene artificial chordae implantation in congenital tricuspid valve abnormalities has been reported to yield satisfactory results in neonates during early post-operation. Nevertheless, given the lack of growth potential of the artificial material, cautious follow-up is mandatory in the long term.



**Figure 1B.** Chorda of the anterior leaflet of the tricuspid valve with fibrotic change, that is separate from papillary muscle

## Conclusion

Early diagnosis of the tricuspid valve papillary muscle rupture is critical, and early surgical repair have a good result during early post-operative period.

## Acknowledgments

None.

## Conflicts of interest

The authors declare that they have no conflict of interest regarding the publication of the current article.

## References

1. Sachdeva R, Fiser RT, Morrow WR, Cava JR, Ghanayem NS, Jaquiss RD. Ruptured tricuspid valve papillary muscle: a treatable cause of neonatal cyanosis. *Ann Thorac Surg.* 2007; 83(2):680-2.
2. Pan JY, Lin CC, Chang JP. Successful repair of neonatal tricuspid regurgitation due to chordae rupture. *J Thorac Dis.* 2018; 10(3):E186-8.
3. Yoon JK, Kim HR, Kwon HW, Kwon BS, Kim GB, Bae EJ, et al. Ruptured tricuspid valve papillary muscle in a neonate with intractable persistent fetal circulation. *Korean Circ J.* 2015; 45(4):340-3.
4. Loftus PD, Arrington CB, Kaza AK. Neonatal flail tricuspid valve: diagnosis and management. *Ann Thorac Surg.* 2014; 98(3):1098-101.